

COULD WE REDUCE UNNECESSARY COLPOSCOPIC EXAMINATIONS?

Introduction:

Cervical cancer was reported as 10th cancer cause among Turkish women and its incidence was announced as 4.0/100.000 by Republic of Turkey Ministry of Health Cancer Department in 2014 (1). The natural progression of cervical cancer demonstrates the importance of screening programs in the early recognition of dysplastic lesions and the prevention of progression to invasive cancer (2). Therefore, the public available screening implementations for appropriate population decrease cancer prevalence adequately (3). Cervical cancer maintains its freshness as a major health problem in less developed countries because of insufficient implemented screening programs, 85% of deaths due to cervical cancer occur in these countries (4).

Turkey implemented a population-based cervical screening program using the Pap smear in 2004, annual coverage rate was only 1–2% (5). It is known that HSIL (High-Grade Squamous Intraepithelial Lesions) could be linked to HPV (Human Papilloma Virus) infection with 95–98% probability (6). HPV screening is objective unlike cervical cytology and its sensitivity for cervical intraepithelial neoplasia detection is greater than cytology-based tests (94%/65%) (7).

Women between 30 and 65 years of age are being screened for population-based test via HPV DNA and conventional cytology in Turkey's nationwide cervical cancer screening program since 2014 (5). Two samples are taken from each applicant for HPV test and liquid-based Pap smear in Community health centers, Cancer early detection screening and training centers and Family health centers. Initially, HPV test is performed, when negative HPV test result, the cytology is not assessed, and she is referred to a new co-test five years later; when positive HPV test result, genotyping of HPV and cytologic assessment are needed. Turkish Society for Colposcopy and Cervical Pathology (TSCCP) recommends that women with HPV-16/18 as well as abnormal cytology, colposcopy should be performed. Women with non-HPV-16/18 and without abnormal cytology should undergo a co-test next year.

American Society for Colposcopy and Cervical Pathology (ASCCP) Colposcopy Standards recommendations address the role of colposcopic examination which relies on visualization of the magnified cervix and guided biopsy sampling (8). ~~Therefore, it furthers to distinguish women with high risk who need treatment for HSIL and micro-invasive cervical cancer (MIC) from women with low risk who undergo surveillance for LSIL for in cervical cancer prevention~~

(8). However, physician's ~~insufficient~~insufficient experience and inadequate biopsy collecting with limited perspective could lead to false negative colposcopy outcomes (9). A reproducible colposcopic evaluation requires determination of individual risk profile, detailed examination and not only identifying the worst lesions for biopsy but also collecting multiple biopsies of cervix with normal view (10). Colposcopy practice could approach "see and treat" as immediate management for young women with HSIL, thereby the number of unnecessary treatments and the associated morbidity could reduce in daily practice (11).

In the present study, we assessed outcomes of target and random biopsies which were taken under colposcopic examination in our clinic with indication of abnormal pap smear or positive HPV test results according to recent guidelines.

Methods:

Patients: The present study included 115 women between the ages 30 and 65 years old who underwent colposcopy with positive HPV test or abnormal liquid-based cervical smear results in Amasya University Gynecology Polyclinic from June 2017 to June 2018 according to community-based cervical cancer screening program. **The inclusion criteria were being 30-65 years old and sexually active.** The exclusion criteria were pregnancy, previous cervical treatment and absence of cervical biopsy. Demographic data, colposcopy indications, HPV genotypes, cytology and biopsy results were assessed retrospectively. The study protocol was reviewed and approved by the hospital management.

Procedures: HPV samples were analyzed using Hybrid Capture 2 for HPV types 16, 18, and the other 11 high-risk HPV types (31, 33, 35, 39, 45, 51, 52, 56, 58, 59, and 68). Cytology samples were obtained into liquid-based preparations (Thin Prep Pap Test) and were graded according to the 2001 Bethesda system. The cytological classifications were: within normal limits (negative), atypical squamous cells of undetermined significance (ASC-US), atypical glandular cells (AGC), atypical squamous cells cannot exclude high grade squamous intraepithelial lesion (ASC-H), low-grade squamous intraepithelial lesion (LSIL), high-grade squamous intraepithelial lesion (HSIL), squamous cell carcinoma (SCC); adenocarcinoma in situ (AIS), or adenocarcinoma (ADC).

Cytology-positive and/or HPV-positive women underwent electronic binocular colposcopy (OCSS-BA, Olympus, China) examination. After squamo-columnar junction visualization and

3% acetic acid application, histological specimens were taken ~~either~~ from suspected areas where comprised aceto-white areas, atypical vascularization in the transformation zone as target **biopsy** or **as** randomly if there were no lesion via cervical biopsy forceps with 5 to 6 mm jaws. Routine endocervical curettage was performed to all patients. ~~Overall colposcopic examinations and biopsies were performed by three gynecologists, and histopathologic evaluations were reviewed by two pathologists following a double-blind method.~~ Lower Anogenital Squamous Terminology (LAST) classification system was used for typing the cervical lesions, as low-grade squamous intraepithelial lesion (LSIL) and high-grade squamous intraepithelial lesion (HSIL) (12). Follow-up and treatment of patients were managed according to the 2012 ASCCP Guidelines.

Statistical analysis: All data were analyzed with Statistical Package for the Social Sciences (SPSS) software (Version 22.0, SPSS Inc., Chicago, IL, USA). Descriptive variables were presented as mean \pm standard deviation and median (min-max) for continuous variables; number and percentage for categorical data. Relationships between categorical variables were assessed by Fisher's Chi-square test (Fisher's Exact test). Statistical significance was accepted as $p < 0.05$.

Results:

The median age of patients was 45 (range 30-65 years). 20 women had no HPV infection. The commonest HPV genotypes ~~were~~**was** 16, followed by 18, 51, 31 and 52. The rates of high-risk HPV genotypes 16, 18, 16/18 and non-HPV-16/18 were found 28.7%, 15.6%, 10.4%, and 48.7%, respectively. 25 women had low risk HPV and 70 women had high risk HPV. The rates of pap-smear cytology; ASC-US, LG-SIL and HG-SIL were found to be 30.4%, 9.6%, and 6.1%, respectively. 62 women had normal pap smear results. There was no relationship between the risk groups of HPV genotypes and pap-smear results ($p > 0.05$). However, majority of women with HSIL had also high-risk HPV, especially HPV 16 genotype.

One to four punch biopsies with endocervical curettage were taken in all colposcopic examinations and the rates of colposcopic biopsy results; LG-SIL and HG-SIL were found to be 20% and 9.6%. Eighty-one women had normal pathology specimens. **The relationship with HPV types, cytology and pathology results of all colposcopy performance was presented in Table 1.** When we evaluated the outcomes of histopathology; HG-SIL was frequently detected with HPV-16 genotypes. **The relationship with HPV 16, 18, 16/18 types, cytology and pathology results of all colposcopy performance was presented in Table 2.**

When the number of punch biopsies increased, high-grade lesions were identified greatly ($p=0.01$). ~~When two and more biopsies were taken randomly with normal visual colposcopy, HGSIL were mostly encountered~~ **HGSIL were mostly encountered, when two and more biopsies were taken randomly with normal visual colposcopy** (Chart 1). When one biopsy was taken from target lesion, they were usually resulted with normal pathology. **We detected LGSIL pathology with one, two, three, four and more biopsies as the same plausibility, however, HGSIL pathology was more frequently detected with three and more biopsies ($p<0.05$).**

Table 1: The relationship with HPV types, cytology and pathology **results** of all colposcopy ~~performance.~~**performance.**

	HGSIL	LGSIL	Normal pathology	TOTAL
HPV risk classification				
High risk HPV	11	17	42	70
Low risk HPV	0	6	19	25
Negative HPV	0	0	20	20
Pap-smear results				
HSIL	4	1	2	7
LSIL	4	5	2	11
ASCUS	3	5	27	35
Normal cytology	0	12	50	62
TOTAL	11	23	81	115

Table 2: The relationship with HPV 16, 18 16/18 types and cytology, pathology **results** of all colposcopy performance.

HPV type	Pap- smear results			Pathology results	
	ASCUS	LSIL	HSIL	LGSIL	HGSIL
HPV 16	6	2	2	5	6
HPV 18	-	-	1	5	-
HPV 16/18	1	1	1	2	2

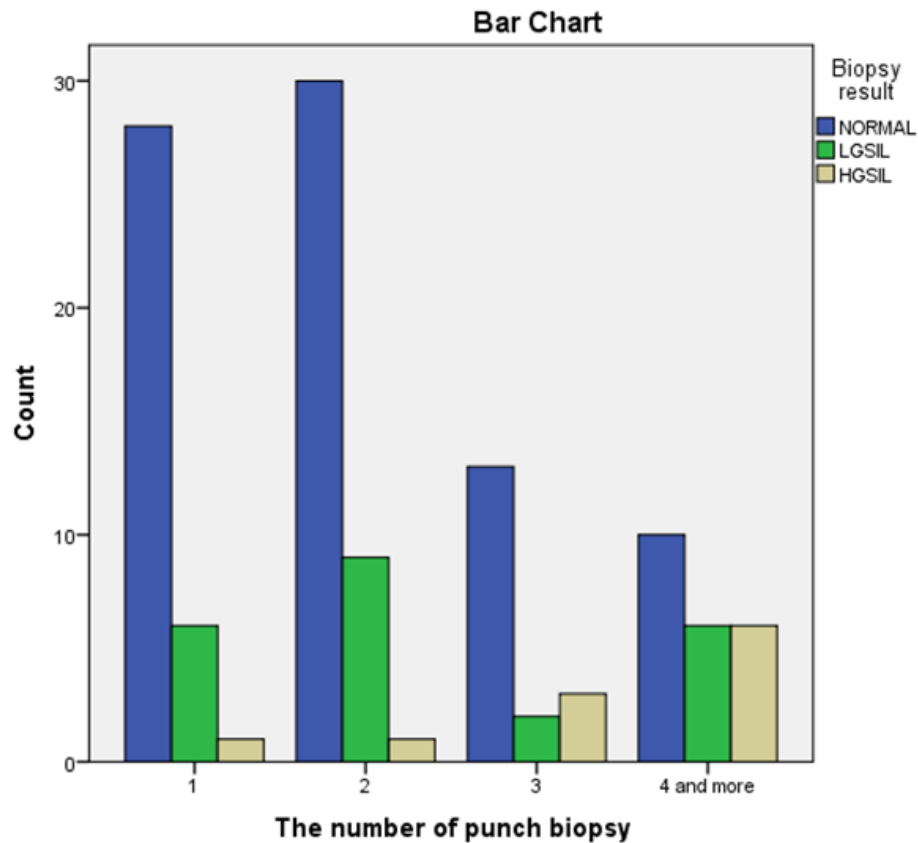


Chart 1: The relationship with the number of punch biopsy number and biopsy results.

Discussion:

Colposcopy practice for patients with positive cervical screening should be managed according to recent guidelines, this can help us to avoid overtreatment of low-grade lesions and undertreatment of high-grade lesions. The ASCCP Colposcopy Standards Committee recommends applying the risk-based colposcopy practice, according to combination of risk markers and a guide how many biopsies should be taken. If the standards are not followed, colposcopy is considered a subjective procedure that is highly depend on observer evaluation.

One hundred and fifteen women with positive HPV results and/or abnormal cytology results were evaluated with colposcopy and punch biopsies were taken immediately in our clinic for the last one year. Whereas thirty-nine women with positive HPV 16 and/or 18 and eighteen women with positive HPV test and abnormal cytology needed colposcopy examination according to the last national cervical cancer screening leaflet. In other words, fifty-eight women had unnecessary colposcopy. This overdiagnosis may occur from fear of skipping cancer diagnosis. If we applied colposcopy for only fifty-seven women, we could

underdiagnose four LGSILs. The progression of cervical intraepithelial neoplasms to cancer take a long time, miss diagnosed patients in a screening could catch in the next screening. Twelve women with LGSIL pathology had normal pap-smear results. If we apply colposcopy for women with only abnormal pap smear results, we could miss twelve women. Eventually, we suggested loss of work time could reduce as well as women with HPV could be without anxiety of cancer when we avoid unnecessary colposcopic examinations.

Presence of HSIL cytology, HPV16/18 positivity and high-grade colposcopy impression are scored for risk strata of cervical premalignant disease. It is decided that whether a biopsy will be taken and how many biopsies will be taken (13). An optimal colposcopy strategy may be different for women with low risk versus women with high risk. When we scored, we encountered 59 women with no risk, 30 women with one risk for biopsy taking and we should have taken no biopsy from these women. However, 11 LGSIL and 2 HGSIL subject were missed. The biopsies of those women who did not carry any risk were usually normal. Nevertheless, we suggest that at least one biopsy should be taken if there is one risk score.

Comprehensive examination of cervical lesions by colposcopy and obtaining biopsies from suspicious lesions are primary steps for identification of cervical dysplasia. Therefore, colposcopically directed cervical biopsy plays a major role in diagnosing HSIL and MIC. Single punch biopsy could be insufficient to exclude high grade lesions and may miss up to 40% of prevalent precancers (14). Lesions associated with persistent HPV infection without cytological abnormalities are likely to be small and harder to detect (8).

While traditional colposcopy teaching focused on identifying the worst lesion for biopsy, recent study suggested that multiple nontargeted biopsies may improve accuracy (15). Moreover, increasing the number of cervical biopsies procedure may improve the diagnostic accuracy. A study demonstrated that taking three biopsies or more was significantly more accurate than taking two biopsies or less (16). 4-quadrant random biopsy protocols performed on areas with no signs of disease, found high grade lesions in 13%-37% of the cases (17). Random biopsies can detect significant disease with type 16 and 18 infections, even if no lesions appear on colposcopy (18). We detected that the presence of cervical dysplasia increases as the number of biopsies increases. We might possibly miss the cervical dysplasia when we collected one or two biopsies due to colposcopic examination. We suggested that at least two target biopsies ~~were~~**are** taken from positive lesions on colposcopic visualization or 4-quadrant random biopsy ~~was~~**is** taken from clear areas in the transformation zone of cervix. In this way, a ~~prealign~~**prealignant** or malignant lesion can be detected if it is there.

Limitations of the study:

Our study has some limitations as, it is a cross-sectional study which consist only last one and half year's ~~colposcopic~~ **colposcopy** examinations. The study population was small, so some statistical calculations did not reach any significance. More comprehensive studies with large sample size are needed. **Overall colposcopy examinations and biopsies were performed by three gynecologists, and histopathology evaluations were reviewed by two pathologists following a double-blind method.**

Conclusion:

Primary screening and triage strategies has an important impact on the population that are referred to colposcopy by family doctor. Continuous training programs and certification are necessary for reproducible ~~standardize~~ **standard** colposcopy **practice**. International evidence-based recommendations are essential procedures for clinicians in the colposcopy practice. Each HPV positivity should not be referred to colposcopy. Therefore, clinicians should increase the number of biopsies which they collected during colposcopy without hesitation.

References

1. Dogan O, Yildiz A, Pulatoglu C. Management of abnormal cytology results and correlation of cytopathologic results accompanied by colposcopy in our clinic. *Clin Exp Med* 2017; 2(3): 62-5.
2. Saslow D, Solomon D, Lawson HW, Killackey M, Kulasingam SL, Cain J. American Cancer Society, American Society for Colposcopy and Cervical Pathology, and American Society for Clinical Pathology screening guidelines for the prevention and early detection of cervical cancer. *CA: a cancer journal for clinicians* 2012; 62(3), 147-72.
3. Turkish Cervical Cancer and Cervical Cytology Research Group. Prevalence of cervical cytological abnormalities in Turkey. *International Journal of Gynecology & Obstetrics* 2009; 106(3), 206-9.
4. Gultekin M, Zayifoglu Karaca M, Kucukyildiz I, Dundar S, Boztas G, Semra Turan H. Initial results of population based cervical cancer screening program using HPV testing in one million Turkish women. *International journal of cancer* 2018; 142(9), 1952-8.
5. Petry KU, Cox JT, Johnson K, Quint W, Ridder R, Sideri M, Behrens CM. Evaluating HPV-negative CIN2+ in the ATHENA trial. *International journal of cancer* 2016; 138(12), 2932-9.
6. Arbyn M, Ronco G, Anttila A, Meijer CJ, Poljak M, Ogilvie G, Peto J. Evidence regarding human papillomavirus testing in secondary prevention of cervical cancer. *Vaccine* 2012; 30, 88-99.
7. Massad LS, Einstein MH, Huh WK, Katki HA, Kinney WK, Schiffman M, Lawson HW. 2012 updated consensus guidelines for the management of abnormal cervical cancer screening tests and cancer precursors. *Obstetrics & Gynecology* 2013; 121(4), 829-46.
8. ~~Wentzensen N, Massad LS, Mayeaux Jr EJ, Khan MJ, Waxman AG, Einstein MH, Chelmow D. Evidence based consensus recommendations for colposcopy practice for cervical cancer prevention in the United States. *Journal of lower genital tract disease* 2017; 21(4), 216-22.~~ Massad LS, Einstein MH, Huh WK, Katki HA, Kinney WK, Schiffman M, Solomon D, Wentzensen N, Lawson HW; 2012 ASCCP Consensus Guidelines Conference. 2012 updated consensus guidelines for the management of abnormal cervical cancer screening tests and cancer precursors. *Obstet Gynecol.* 2013; 121(4):829-46.

9. Hu SY, Zhang WH, Li SM, Li N, Huang MN, Pan QJ, Qiao YL. Pooled analysis on the necessity of random 4-quadrant cervical biopsies and endocervical curettage in women with positive screening but negative colposcopy. *Medicine* 2017; 96(17).
10. Chen Q, Du H, Pretorius RG, Wang C, Yang B, Wang G, Wu R. High-grade cervical intraepithelial neoplasia detected by colposcopy-directed or random biopsy relative to age, cytology, human papillomavirus 16, and lesion size. *Journal of lower genital tract disease* 2016; 20(3), 207-12.
11. Underwood M, Arbyn M, Parry-Smith W, De Bellis-Ayres S, Todd R, Redman CWE, Moss EL. Accuracy of colposcopy-directed punch biopsies: a systematic review and meta-analysis. *BJOG: An International Journal of Obstetrics & Gynaecology* 2012; 119(11), 1293-301.
12. Darragh TM, Colgan TJ, Cox JT, Heller DS, Henry MR, Luff RD, Wilkinson EJ. The lower anogenital squamous terminology standardization project for HPV-associated lesions: background and consensus recommendations from the College of American Pathologists and the American Society for Colposcopy and Cervical Pathology. *Archives of pathology & laboratory medicine* 2012; 136(10), 1266-97.
13. Wentzensen N, Schiffman M, Silver MI, Khan MJ, Perkins RB, Smith KM, Mayeaux Jr EJ. ASCCP colposcopy standards: risk-based colposcopy practice. *Journal of lower genital tract disease* 2017; 21(4), 230-4.
14. Wentzensen N, Walker JL, Gold MA, Smith KM, Zuna RE, Mathews C, Tenney M. Multiple biopsies and detection of cervical cancer precursors at colposcopy. *Journal of Clinical Oncology* 2015; 33(1), 83.
15. Moss EL, Hadden P, Douce G, Jones PW, Arbyn M, Redman CW. Is the colposcopically directed punch biopsy a reliable diagnostic test in women with minor cytological lesions?. *Journal of lower genital tract disease* 2012; 16(4), 421-6.
16. Fan A, Zhang L, Wang C, Wang Y, Han C, Xue F. Analysis of clinical factors correlated with the accuracy of colposcopically directed biopsy. *Archives of gynecology and obstetrics* 2017; 296(5), 965-72.
17. Pretorius RG, Zhang WH, Belinson JL, Huang MN, Wu LY, Zhang X, Qiao YL. Colposcopically directed biopsy, random cervical biopsy, and endocervical curettage in the

diagnosis of cervical intraepithelial neoplasia II or worse. *American journal of obstetrics and gynecology* 2004; 191(2), 430-4.

18. Huh WK, Sideri M, Stoler M, Zhang G, Feldman R, Behrens CM. Relevance of random biopsy at the transformation zone when colposcopy is negative. *Obstetrics & Gynecology* 2014; 124(4), 670-8.