

TRANSITIONAL CELL CARCINOMA WITHIN A BLADDER DIVERTICULUM: CT FINDINGS AND PATHOLOGIC CORRELATION

A. Seçil Ekşioğlu

ABSTRACT:

A case of transitional cell carcinoma within a bladder diverticulum is presented. A 71-year-old man with a previous history of prostate carcinoma presented with hematuria and a burning sensation during urination. CT IVP detected a small polypoid mass within a bladder diverticulum, suspicious for a malignancy. A biopsy was performed during cystoscopy and pathology revealed a high grade papillary urothelial carcinoma with no muscularis propria identified. He underwent radical cystectomy and was followed up for recurrence. The clinicopathologic characteristics of diverticular neoplasms and the importance of CT in the diagnosis of overlooked lesions and staging are reviewed.

Key words: Diverticulum, Transitional Cell Carcinoma

MESANE DİVERTİKÜLÜ İÇERİSİNDE GELİŞEN DEĞİŞİCİ HÜCRELİ KARSİNOM: BT BULGULARI VE PATOLOJİK KORELASYON

ÖZ:

Mesane divertikülü içerisinde gelişen değişici hücreli karsinom vakası sunulmaktadır. On yıl önce prostat karsinomu tanısı alan 71 yaşında erkek hasta hematurisi ve idrarda yanma hissi ile başvurdu. Kontrastlı BT IVP sonucunda bir mesane divertikülü içerisinde malignansi açısından şüpheli küçük polipoid kitle saptandı. Sistoskopi sırasında lezyondan biopsi örnekleri alındı ve patoloji sonucu muskularis propria tabakasının izlenmediği yüksek dereceli papiller üroelial karsinom olarak geldi. Negatif metastaz taraması sonrası radikal sistektomi yapıldı ve hasta takibe alındı. Bir vaka nedeniyle divertiküler neoplazinin klinikopatolojik özellikleri ve BT nin özellikle gözden kaçan vakaların tanısında ve evrelemedeki önemi hatırlatılmaktadır.

Anhtar Kelimeler: Divertikül, Değişici Hücreli Karsinom

INTRODUCTION:

Neoplasms within a bladder diverticulum have attracted attention because of their relatively difficult diagnosis and early invasion secondary to the small amount of muscle (if any).

The incidence of intradiverticular neoplasms was reported to be between 0.8% and 10% in most studies^{1,2}; however, there is at least one study that claims that this incidence might be as high as 50%³.

The limitations of cystoscopy and conventional radiologic examinations make cross-sectional imaging modalities mandatory, especially for the diagnosis of diverticula with narrow necks.

Here we present the CT IVP findings of a patient with an intradiverticular tumor and review the importance of CT in the diagnosis and staging.

CASE REPORT:

A 71-year-old man with a history of prostate carcinoma 10 years previously presented with hematuria and a burning sensation during urination. He denied other symptoms such as nausea, vomiting, fevers, or chills. His physical examination was unremarkable except for mild suprapubic tenderness to deep palpation. He had had several recent urinary tract infection episodes in the previous 5 months but this time persistent dysuria in spite of the infection treatment prompted further imaging.

He underwent a CT IVP examination. A single helical acquisition was performed from the tops of the kidneys to through the bottom of the bladder using 1.35:1 pitch, 120 kVp, and 160 mA and without using any IV contrast. No oral contrast agent other than water was used. After the administration of IV contrast agent 90 second and 10 minute delayed axial images were obtained using the same parameters. A 10 minute delayed anteroposterior scout view from the diaphragm to the base of the bladder was also a part of the procedure.

CT IVP revealed a small polypoid mass within a bladder diverticulum, suspicious for a malignancy, without any peripheral fat, which could be suggestive of perivesicular invasion (Fig 1a-b). No concurrent abnormality was detected within the collecting systems, ureters, or urinary bladder.

The patient underwent cystoscopy under anesthesia. A large diverticulum on the left lateral wall above the level of the left ureteral orifice was visualized. Within this was an approximately 3 x 2 cm bladder tumor with a papillary appearance. During the procedure multiple biopsy specimens were obtained with cold-cut biopsy forceps before the entire tumor was thoroughly fulgurated (Fig 2). Resection was avoided since the tumor was within a diverticulum.

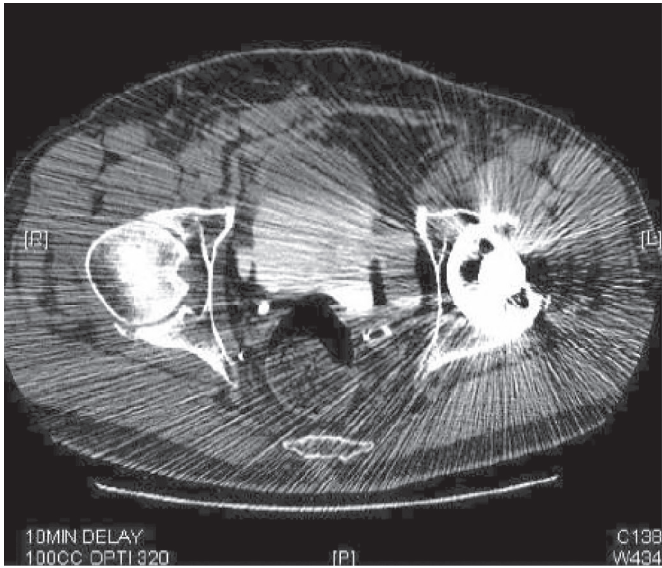


Figure 1a: 10 minute-delayed images of the CT IVP show a left sided bladder diverticulum with a urine contrast level. The presence of a left hip prosthesis causes artifacts and diminishes the image quality

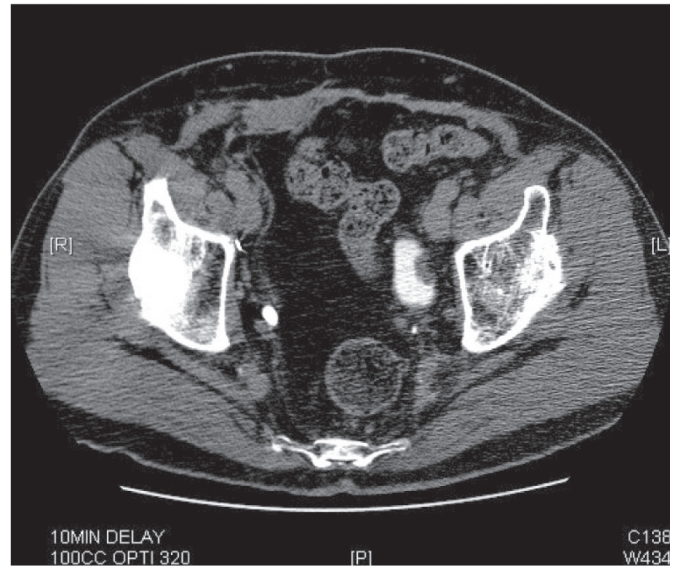


Figure 1b: A small polypoid mass lesion is noted within the upper portion of the bladder diverticulum, which most possibly represents a transitional cell carcinoma. No evidence of peridiverticular extension was identified.

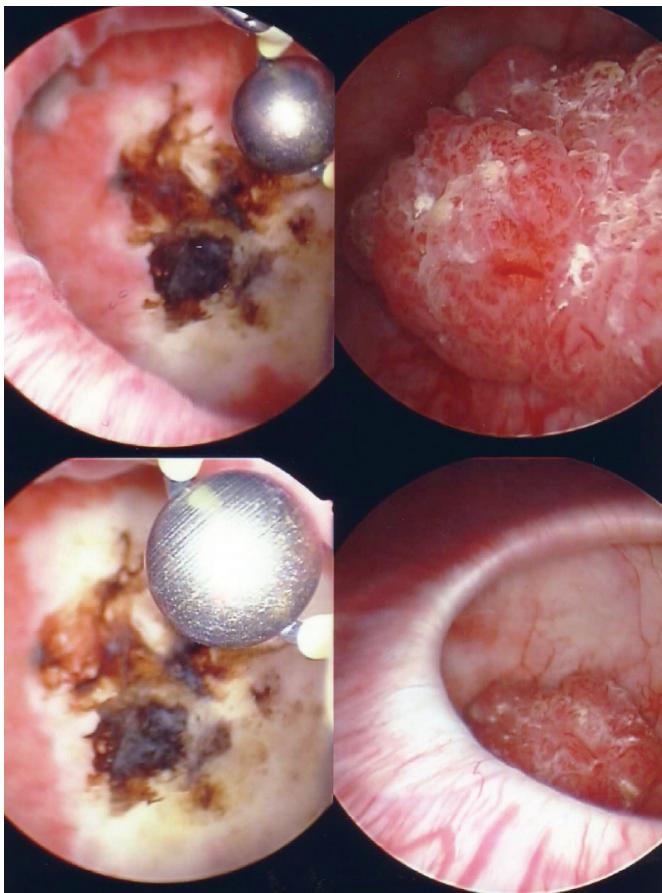


Figure 2: The cystoscopic image demonstrates the papillary tumor within the large diverticulum seen within the left lateral wall.

Pathology revealed a high grade papillary urothelial carcinoma with no muscularis propria identified (Fig 3a,b).

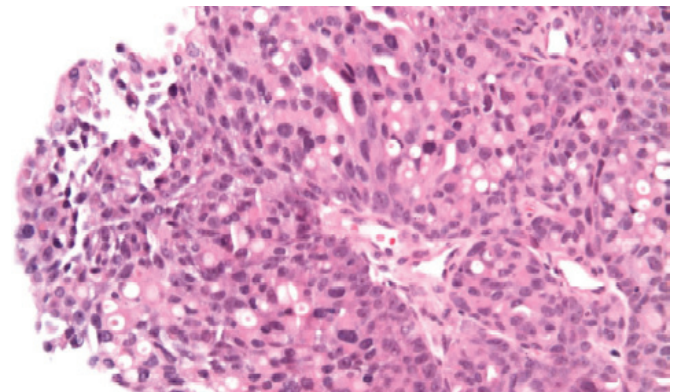


Figure 3a: In the pathology slide the stroma of the tumor is noted with a central blood vessel in the middle, supporting the greatly thickened epithelial layer consisting of atypical cells consistent with high-grade papillary urothelial carcinoma.

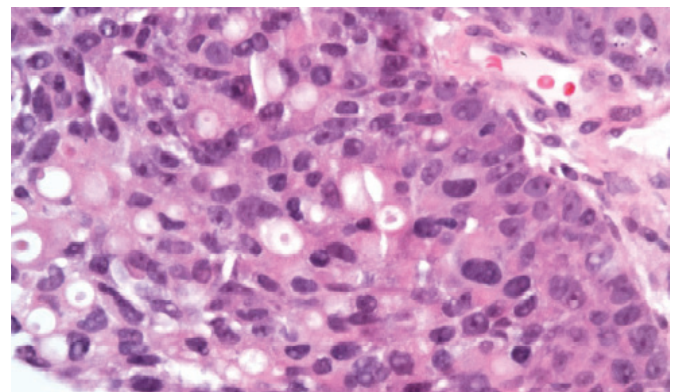


Figure 3b: The magnified image better demonstrates the pleomorphic neoplastic cells with prominent nucleoli. No muscularis propria is identified in these specimens obtained during cystoscopy with cold-cut biopsy forceps.

After negative metastatic screening including chest CT and bone scan a radical cystectomy with the creation of an ileal conduit was performed. There was no evidence of extravascular tumor invasion or lymphatic involvement.

Pathology of the left bladder diverticulum revealed only a minimal (smaller than 0.5 cm microscopically) residual carcinoma that invaded through the attenuated muscularis propria. The carcinoma was limited within the surgical margins. No evidence of neoplasia was detected within the remaining bladder.

The patient will be followed up for any disease recurrence.

DISCUSSION:

Diverticula of the bladder are outpouchings of urethelium through muscular wall defects and frequently do not empty adequately secondary to the lack of muscle fibers in their walls, narrow ostium, or large size. Urinary stasis within the diverticula is likely the cause of chronic inflammation, recurrent infection, and development of dysplasia, leukoplakia, and squamous metaplasia in 80% of all diverticula ⁴⁻⁶.

If there is a diverticulum within a bladder the possibility of development of a neoplasm will be higher than that of a normal bladder, ranging from 0.8% to 10%, and most neoplasms would be expected within the diverticulum, the most common type being transitional cell carcinoma (78%). The other types are squamous cell carcinoma (17%), a combination of transitional cell and squamous cell carcinoma (2%), and adenocarcinoma (2%) ⁷.

Regardless of the type of the neoplasm, bladder tumors arising within a diverticulum are a double challenge because of the difficult diagnosis and early invasion.

Conventional radiography is of limited use in bladder cancer. Calcifications and a pelvic mass large enough to be visible on plain radiography are rare⁸. Generally bladder diverticula are evaluated by cystoscopy and intravenous pyelography (IVU). However, even with these techniques, diverticular neoplasms tend to be underdiagnosed ⁹⁻¹¹. Although bladder position or tethering, wall irregularities, and filling defects may offer clues pointing to the presence of neoplastic disease, unfortunately only 60% of all known bladder tumors can be demonstrated with intravenous urography ⁸. Cystoscopy frequently fails to disclose a tumor within a diverticulum particularly secondary to a narrow orifice that a cystoscope cannot enter. If the tumor lumen or orifice is completely obliterated by the neoplasm it might be impossible to visualize the diverticulum by IVU or cystoscopy ¹².

CT has been found to be useful in the staging of the bladder carcinoma, although prior surgery, prior radiation therapy, or inadequate opacification techniques can lead to overstaging¹³⁻¹⁵. Nevertheless, the diagnostic reliability of CT increases with disease progression ^{6,15}. Our case did not show any evidence of perivesicular involvement; thus pathology revealed microscopic invasion through the attenuated muscularis propria, which we do not expect to see by CT.

Diverticular neoplasms have a worse prognosis than regular bladder neoplasms secondary to early invasion. Since the bladder diverticula have minimal, if any, muscular wall, neoplasms rapidly progress from T1 to T3. Some authors have suggested that for intradiverticular neoplasms stage pT2 should be omitted and stage pT3 should follow pT1^{16,17}. However, at the moment there are insufficient data for the creation of a new staging system for diverticular tumors. On the other hand, a degree of relief lies in the idea that from a biological behavioral standpoint an actually T1 neoplasm that has invaded the peridiverticular fat may not behave as aggressively as a real T3 since it might not have gained full invasive potential. Common sense is in favor of treating T1 tumors more aggressively¹⁸.

Our case, being a T2/3, was treated with a radical cystectomy with the creation of an ileal conduit.

In summary, whenever a bladder diverticulum is observed we should keep in mind that there is an increased risk for neoplasm, particularly within the diverticulum. Neoplasms within bladder diverticula present diagnostic difficulty followed by staging difficulty. CT can be useful for both problems. It is good for catching cases missed by the other modalities and can be used for assessing the depth of invasion and nodal involvement and therefore can help to determine the approach for treatment.

Correspondence Address: A. Seçil EKŞİOĞLU

*S.B.Dr. Sami Ulus Kadın Doğum ve
Çocuk Eğitim ve Araştırma Hastanesi,
Radiology
Ankara, Türkiye
Tel: 0532 488 37 63
E-mail: yucelsecil@yahoo.com*

REFERENCES:

- 1- Lawrence WW (Ed): Current Surgical Diagnosis and treatment, 10th ed. Englewood Cliffs, New Jersey, Prentice-Hall, 1994; 952-954.
- 2- Melekos MD, Asbach HW, Barbalias GA: Vesical diverticula: etiology, diagnosis tumorigenesis and treatment. Analysis of 74 cases. Urology 1987; 30: 453-457.
- 3- Wasserman NF, Zhang G, Posalaky IP, Reddy PK: Ureteral pseudodiverticula: frequent association with uroepithelial malignancy. Am J Roent 1991; 157: 69-72.
- 4- Gerridzen RG, Futter NG: Ten year review of vesical diverticula. Urology 1982; 20: 33-35.
- 5- Peterson LJ, Paulson DF, Glenn JF: The histopathology of vesical diverticula. J Urol 1973; 110: 62-64.
- 6- Lowe FC, Goldman SM, Oesterling JE: Computerized tomography in evaluation of transitional cell carcinoma in bladder diverticula. Uroradiology 1989; 34: 390-395.
- 7- Baniel J, Vishna Tali: Primary transitional cell carcinoma in vesical diverticula. Urology 1997; 50: 697-699.
- 8- Matta EJ, Kenney AJ, Barré GM, Vanlangendonck RM Jr: Intradiverticular bladder carcinoma. Radiographics 2005; 25: 1397-1403.

- 9- Abeshouse BS, Goldstein RG: Primary carcinoma in a diverticulum of the bladder: a report of four cases and a review of the literature. J Urol 1943; 49 534-536.
- 10- Knappenberger ST, Uson AC, Melicow MM: primary neoplasm occurring in vesical diverticula: report of 18 cases. J Urol 1960; 83: 153-159.
- 11- Donalski M, White EM, Ghahremani GG, Patel SK: Carcinoma arising in urinary bladder diverticula: Imaging findings in six patients. AJR 1993; 161: 817-820.
- 12- Yağci C, Atasoy C, Fitoz S, Akyar S: Cross-sectional imaging findings in intradiverticular tumors: Case report. Tani Girisim Radyol 2003 Dec; 9: 452-455
- 13- Seidelman FE, Cohen WN, Bryan PJ: Computed tomographic staging of bladder neoplasms. Rad Clin North Am 1977; 15: 419-440.
- 14- Hamlin DJ, Cockett ATK: Modification for computerized tomographic staging of infiltrative bladder carcinoma. J Urol 1980; 123: 489-491.
- 15- Vock P, Haertel M, Fuchs WA et al: Computerized tomography in staging of carcinoma of the urinary bladder: Br J Urol 1982; 54: 158-163.
- 16- Redman JF, McGinnis TB, Bissada NK: Management of neoplasms in vesical diverticula. Urology 1976; 50: 492-494.
- 17- Rubin P: Current concepts in genitourinary oncology: a multidisciplinary approach. J Urol 1971 106: 315-338.
- 18- Golijanin D, Yossepowitch O, Beck SD et al: Carcinoma in a bladder diverticulum: Presentation and treatment outcome. The Journal of Urology 2003; 170: 1761-1764.