

# INVASIVE GROUP A BETA-HEMOLYTIC STREPTOCOCCAL INFECTION IN CHILDREN IN THE 2000'S: A CASE REPORT

Murat Elli<sup>1</sup>, Berna Canter<sup>2</sup>, Çağlar Citak<sup>3</sup>, Sedef Tunaoglu<sup>2</sup>, Mehmet Dogan<sup>4</sup>

## ABSTRACT

Group A beta hemolytic streptococcus (GABHS) causes invasive, non-invasive, and non-suppurative diseases. Reports on the increased incidence of invasive GABHS infections have shown that the majority of these infections occurred in otherwise healthy children, and may be fatal despite early administration of antibiotic treatment. We present a case where rapidly progressive necrotizing pneumonia resulted in sepsis and death. GABHS was isolated from tissue cultures taken from various organs. Necrotizing pneumonia was diagnosed at autopsy. This case indicates that invasive GABHS infections may still be a burden for the healthy children in the 21st century and GABHS must be investigated in children with rapidly progressive pneumonia.

**Key Words:** GABHS, Necrotizing Pneumonia, Sepsis.

## 2000'Lİ YILLARDA ÇOCUKLARDA İNVAZİV A GRUBU BETA HEMOLİTİK STREPTOKOK İNFEKSİYONU: OLGU SUNUMU ÖZ

A grubu beta hemolitik streptokoklar (GABHS) invaziv ya da invaziv olmayan ve nonsüpüratif hastalıklara neden olabilirler. Son yıllarda, erken antibiyotik tedavilerine rağmen ölümcül olabilen invazif GABHS enfeksiyonlarının sağlıklı çocuklarda giderek daha sık karşılaşıldığını gösteren yayınlar artmaktadır. Biz burada ölümlü sonuçlanan ilerleyici nekrotizan pnömöni ve sepsisli bir olguyu sunduk. Otopsi ile nekrotizan pnömöni gösterildi ve organ sürüntü kültürlerinden GABHS izole edildi. Bu olgu invaziv GABHS enfeksiyonun 21. yüzyılda sağlıklı çocuklar için tehlike olduğunu ve hızla ilerleyici nekrotizan pnömöni-lerde GABHS araştırılması gerektiğini göstermektedir.

**Anahtar Kelimeler:** GABHS, Nekrotizan Pnömoni, Sepsis.

## INTRODUCTION

Group A beta-hemolytic streptococcus (GABHS) is a common infective agent in children that causes the widest range of clinical disease in humans of any bacterium. Invasive disease is less common but has a high rate of mortality and long-term morbidity. Resurgence of rheumatic fever, the appearance of streptococcal toxic shock-like syndrome and reports on the increased incidence of invasive diseases via GABHS generated a renewed interest in this microorganism in the late 1980's. Reports on the increased incidence of severe invasive GABHS infections showed that the majority of these infections occurred in otherwise healthy children, and may be fatal despite early administration of antibiotic treatment (1-4). In this report, we present a previously healthy child who died in the emergency room within one hour of his admission. His death was attributed to GABHS sepsis following rapidly progressive pneumonia based on the positive tissue cultures from multiple organs. This case indicates that invasive GABHS infections could be a burden for healthy children in the 21st century.

## CASE REPORT

A 2-year-old boy was admitted to our emergency department with the complaints of fever, somnolence, and cyanotic fingertips. He had been in his usual state of good health until two days before when he began to have fever and fatigue. There were no symptoms of a respiratory tract infection such as sore throat or cough and the fever seemed to respond to the antipyretics. His 5-year-old sister had had signs of an upper respiratory infection before. On the following day, when he developed somnolence and cyanosis on the fingertips, he was admitted to a private outpatient clinic. He was diagnosed with severe pneumonia and was referred to our emergency department for further evaluation and treatment.

On admission, the patient was lethargic. His weight and height were within the normal ranges for his age. He had a body temperature of 35.6 °C and a pulse rate of 140/min. His pulse was hardly palpable and his blood pressure could not be obtained. He had dyspnea with a respiratory rate of 44/min on auscultation. Rales were noted in the upper lobes of the lungs, whereas no breath sound was heard at the basal parts. He had neither an apparent skin infection nor rash.

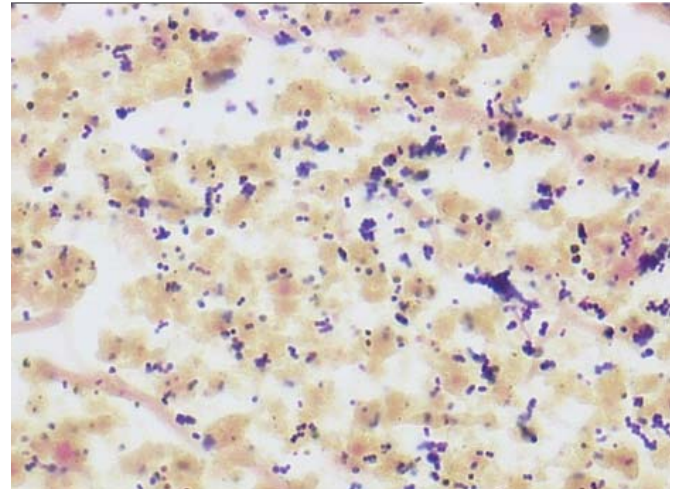
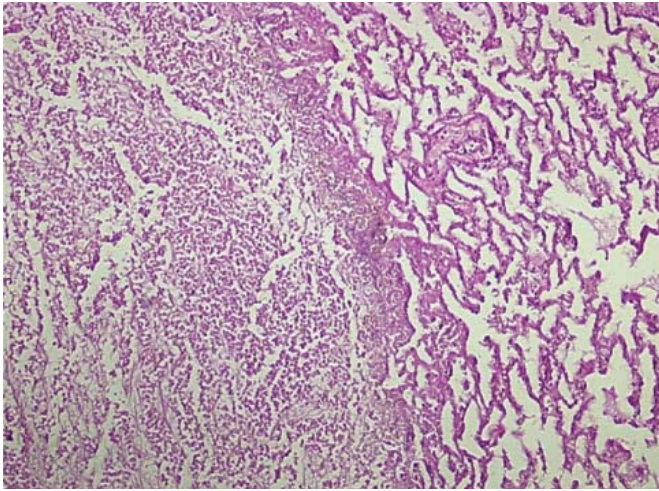
Laboratory results including a complete blood count were as follows: Hb: 10.2 g dl-1, leukocytes: 5,200/mm<sup>3</sup>, platelets: 203,000/mm<sup>3</sup> and a differential count with 82% segmented and 10% banded neutrophils together with toxic granulation. Metabolic acidosis and hypoxia were apparent in his blood gas analysis; pCO<sub>2</sub> was within the normal ranges. A chest X-ray revealed pneumonic infiltration in the lower lobe of the left lung. Since venous access was impossible due to the decreased peripheral perfusion, the intraosseous route was used to restore the circulation; meanwhile, a bone marrow culture was obtained. His breathing progres-

<sup>1</sup> Department of Pediatric Oncology, Medical Faculty, Ondokuz Mayıs University, Samsun

<sup>2</sup> Department of Pediatric Cardiology, Gazi University, Ankara, Turkey

<sup>3</sup> Department of Pediatric Oncology, Gazi University, Ankara, Turkey

<sup>4</sup> Department of Pathology, Medical Faculty, Gazi University, Ankara, Turkey



**Figure 1:** (HE X40) and **Figure 2:** (Gram stain X100): Acute necrotizing pneumonia resulting from inflammatory cell infiltration and interstitial thickening in the lungs together with fibrin accumulation and widespread necrosis within the alveoli.

sively deteriorated and finally necessitated endotracheal intubation. In a short time, he suffered cardiac arrest and did not respond to resuscitation.

Family consent was obtained for a postmortem lumbar puncture and autopsy. The cerebrospinal fluid analysis was normal (protein: 15 mg dl-1, glucose 52 mg dl-1, no cells). In the autopsy, the thymus gland and the lymph nodes were normal. There were inflammatory cell infiltration and interstitial thickening in the lungs together with fibrin accumulation and widespread necrosis within the alveoli due to acute necrotizing pneumonia (Figure 1, 2). In the liver, there was hemophagocytic lymphohistiocytosis secondary to infection. Cultures from the bone marrow, lungs, kidneys, spleen, and liver all yielded GABHS.

Figure 1 (HE X40) and Figure 2 (Gram stain X100): Acute necrotizing pneumonia resulting from inflammatory cell infiltration and interstitial thickening in the lungs together with fibrin accumulation and widespread necrosis within the alveoli.

## DISCUSSION

GABHS accounts for 15% to 30% of cases of acute pharyngitis in children (5). As in streptococcal pharyngitis, acute rheumatic fever and poststreptococcal glomerulonephritis most often occur in children. Apart from pyogenic infections, toxemic GABHS infections were reported, described as a toxic shock-like syndrome. Invasive GABHS infections are more common in adults with other comorbidities although many cases (and almost all in children) occur in otherwise healthy individuals. Varicella infection is the most commonly identified precipitating factor in children. There also may be an association between the use of non-steroidal anti-inflammatory drugs and necrotising fasciitis or invasive disease (6,7). The incidence and the severity of GABHS infections declined dramatically during the second half of the 20th century in developed countries. Since the mid-1980's, an increase in the incidence of invasive infections caused by group A streptococci has been reported in many countries and regions (8,9). In 2000, the in-

cidence of invasive GABHS disease in most industrialized countries was between 1.95 and 3 per 100,000 and mortality rates vary between 10% and 20%. Recent data suggest that invasive GAS infections have occurred at increased rates in developing countries in the past 30 years. It is estimated that more than 660,000 cases of invasive disease resulting in more than 160,000 deaths occur globally each year, most in developing countries (4,10-12). This dramatic rise may be due to changes in specific virulence factors (13,14).

The case presented in this report is a typical example of severe invasive GABHS infection. According to the parents, there was no history or sign of an underlying chronic disease, as in most reported cases of invasive GABHS infections (6,7), and the weight and height of the patient were within the normal ranges for his age. Since there was no family history of immune deficiency or any abnormality in the thymus or lymph nodes at the autopsy, an underlying immune deficiency was unlikely. He developed septic shock following severe progressive pneumonia due to GABHS infection in a relatively short time, which resulted in death. The rapid progression of the respiratory infection into septic shock and death in such an otherwise healthy child was unexpected. However, the recovery of GABHS showed that this was just another new case of invasive GABHS infection similar to the reports mentioned above. Rapid development of respiratory failure and shock after admission to hospitals or deaths on arrival due to GABHS infections as in our case were previously reported (15,16).

Invasive GABHS disease is defined as an infection associated with the isolation of GABHS from a normally sterile body site and includes three overlapping clinical syndromes (CDI). The diagnosis of GABHS can be suspected and confirmed by (1) characteristic clinical features, (2) isolation of causative agent, (3) serologic tests, and (4) other less specific tests. The blood, cerebrospinal fluid, peritoneal fluid, and tissue biopsy specimen culture are helpful in patients with skin or soft tissue involvement. Results of blood cultures from patients with sepsis without an apparent focus of infection may also show GABHS (3,17). In order to investigate the cause of the death, we obtained necropsy and cultures from several organs,

which led to the diagnosis of widespread GABHS infection. To our knowledge, there is no report in the literature recovering GABHS from cultures of different organs of patients with invasive GABHS infections. Systemic signs or symptoms such as fever, chills, or vomiting, and findings of septic shock and bacteremia (positive blood cultures) were the clues for invasiveness. Invasion of multiple organs by GABHS as shown in this case gives an idea about how virulent the GABHS are in fatal or nearly fatal cases. It can be evidence supporting the hypothesis that the resurgence of invasive GABHS infections in the last two decades is due to the increased virulence of this organism. To our knowledge, there was only one case report from Turkey about invasive GABHS disease and necrotizing pneumonia similar to ours (16). Invasive GABHS infections in the literature are mainly reports from developed countries. This case may show that such invasive infections due to GABHS could occur in healthy children in developing countries where ordinary GABHS infections and their complications are much more common.

An accurate diagnosis of GABHS infection is important because it is the only common form of acute pharyngotonsillitis for which antibiotic therapy is definitely indicated. Antimicrobial therapy is indicated for individuals with symptomatic pharyngitis after the presence of GAS in the throat has been confirmed by either throat culture or rapid antigen detection tests (5,18,19). Antibiotic therapy can shorten the clinical course of GABHS pharyngotonsillitis, reduce the rate of transmission, and prevent suppurative and nonsuppurative complications, such as peritonsillar abscess and acute rheumatic fever (20). Routine chemoprophylaxis against GABHS pharyngitis for sibling contacts is not recommended (21). Physicians contemplating chemoprophylaxis for household contacts should consider factors including the severity of disease in the index case, the extent of contact with the index case, underlying conditions in contacts that may increase the risk of disease or mortality (e.g., advanced age, immunosuppression, diabetes mellitus, varicella infection), and the costs and potential adverse effects of chemoprophylaxis (17).

In conclusion, the increased incidence of invasive GABHS infections seems to be due to the increased virulence of this microorganism. The recovery of GABHS from multiple organ sites in fatal cases may support this hypothesis. As obtaining cultures and biopsies from patients with unknown cause of death would give a better idea on the incidence of this disease it is strongly recommended. It seems that invasive GABHS infections are also an important problem in developing countries and will continue to be a problem for healthy children in the future.

*Correspondence Address*

Murat Elli

İstasyon Mh. Abdülhakhamid Cad.

Yunus Emre Ap. No:30/6 55060 Samsun TURKEY

Tel: 0-362-3121919 / 2391 Fax: 0-362-4576041

E-mail. ellimurat@yahoo.com

## REFERENCES

1. Stevens DL, Tanner MH, Winship J, et al. Severe group A streptococcal infections associated with a toxic shock-like syndrome and scarlet fever toxin A. *N Engl J Med* 1989; 321: 1-7.
2. Belani K, Schlievert PM, Kaplan EL, Ferrieri P. Association of exotoxin producing group A streptococcus and severe disease in children. *Pediatr Infect Dis J* 1991; 10: 351-354.
3. Steer AC, Danchin MH, Carapetis JR. Group A streptococcal infections in children. *Journal of Paediatrics and Child Health* 2007;43:203-213
4. Carapetis JR, Steer AC, Mulholland EK, Weber M. The global burden of group A streptococcal diseases. *Lancet Infect. Dis.* 2005; 5: 685-94.
5. Gerber MA, Shulman ST. Rapid diagnosis of pharyngitis caused by group A streptococci. *Clin Micro Rev.* 2004; 17: 571-580.
6. Hoge CW, Schwartz B, Talkington DF, Breiman RF, MacNeill EM, Englender SJ. The changing epidemiology of invasive group A streptococcal infections and the emergence of streptococcal toxic shock-like syndrome: a retrospective population-based study. *JAMA.* 1993; 269: 384-389.
7. Davies HD, McGeer A, Schwartz B et al. Invasive group A streptococcal infections in Ontario, Canada. *N Engl J Med.* 1996; 335: 547-554.
8. O'Brien KL, Beall B, Barrett NL et al. Epidemiology of invasive group A streptococcus disease in the United States, 1995-1999. *Clin Infect Dis* 2002; 35: 268-276.
9. Carapetis JR, Robins-Browne R, Martin D et al. Increasing severity of invasive group A streptococcal disease in Australia: clinical and molecular epidemiological features and identification of a new virulent M-non-typeable clone. *Clin Infect Dis* 1995; 21: 1220-1227.
10. Weir E, Main C. Invasive group A streptococcal infections. *CMAJ.* 2006;175:32
11. Kaplan EL. Recent epidemiology of Group A streptococcal in North America and abroad: an overview. *Pediatrics.* 1996; 97: 945-948.
12. Siedler A, Reinert RR, Toschke M, Al-Lahham A. Regional differences in the epidemiology of invasive pneumococcal disease in toddlers in Germany. *The Pediatric Infectious Disease Journal.* 2005; 24: 1114-1115.
13. Vlamincx BJM, Mascini EM, Schellekens J et al. Site-specific manifestations of invasive group A streptococcal disease: type distribution and corresponding patterns of virulence determinants. *J Clin Microbiol* 2003; 41: 4941-4949.
14. Chatellier S, Ihendyane N, Kansal RG. Genetic relatedness and superantigen expression in group A streptococcus serotype M1 isolates from patients with severe and non-severe invasive diseases. *Infect Immun* 2000; 68: 3523-3534.
15. Montgomery VL, Bratcher D. Complications associated with severe invasive streptococcal syndrome. *J Pediatr* 1996; 129: 602-604.
16. Cengiz AB, Kanra G, Caglar M, Kara A, Gucer S, Ince T. Fatal necrotizing pneumonia caused by group A streptococcus. *J Paediatr Child Health* 2005; 40: 69-71
17. Committee on Infectious Diseases. Severe Invasive Group A Streptococcal Infections: A Subject Review. *Pediatrics* 1998; 101; 136-140.
18. Gerber MA. Diagnosis and treatment of pharyngitis in children. *Pediatr Clin N Am.* 2005; 52: 729-747.
19. Mirza A, Wludyka P, Chiu TT, Rathore MH. Throat culture is necessary after negative rapid antigen detection tests. *Clin Pediatr (Phila)* 2007; 46: 241-47.
20. Brook I, Dohar JE. Management of group A beta-hemolytic streptococcal pharyngotonsillitis in children. *J Fam Pract.* 2006; 55: S1-11; quiz S12.
21. Kikuta H, Shibata M, Nakata S, Yamanaka T, Sakata H, et al. Efficacy of Antibiotic Prophylaxis for Intrafamilial Transmission of Group A  $\beta$ -Hemolytic Streptococci. *Pediatr Infect Dis J* 2007; 26: 139-141.