

A MATERNAL DEATH COMPLICATED BY SYSTEMIC LUPUS ERYTHEMATOSUS: A CASE REPORT

Selma Çivi, Ruhuşen Kutlu

ABSTRACT

This paper is a case report of a pregnant woman with systemic lupus erythematosus (SLE) complicated by preeclampsia, nephritis, pericardial effusion, and massive pulmonary congestion. Nephritis is known to be one of the most serious complications of SLE and is a strong predictor of poor outcome. She was a primigravida in the 27th week of gestation. In our patient, postgestational lupus flare up was noted. Risk factors included lower serum albumin, elevated serum ANA and anti-ds DNA antibody, proteinuria, pericardial effusion, massive pulmonary congestion, and hypertension. Thus, our patient had many risk factors to develop preeclampsia and she died.

Key Words: Systemic Lupus Erythematosus, Pregnant Woman.

SİSTEMİK LUPUS ERİTEMATOZUS İLE KOMPLİKE BİR ANNE ÖLÜMÜ: OLGU SUNUMU

ÖZ

Bu makale preeklampsi, nefrit, perikardiyal effüzyon ve yaygın pulmoner konjesyon ile komplike olan sistemik lupus eritematozuslu gebe bir kadının olgu sunumudur. Nefrit SLE'nin en ciddi komplikasyonlarından biri olarak bilinir ve kötü prognoz en güçlü göstergesidir. Olgunun ilk gebeliği idi ve 27. gebelik haftasında idi. Bizim hastamızda gebelik sonrasında lupus hastalığı alevlenmişti. Serum albümin düzeyinde düşme, ANA ve anti-ds DNA antikor yüksekliği, proteinüri, perikardiyal effüzyon, masif pulmoner konjesyon ve hipertansiyon risk faktörleri idi. Böylece, birçok risk faktörü taşıyan hastamızda preeklampsi gelişti ve hasta öldü.

Anahtar Kelimeler: Sistemik Lupus Eritematozus, Gebe Kadın.

INTRODUCTION

Systemic lupus erythematosus (SLE) is a chronic inflammatory connective tissue disease commonly diagnosed after the age of 20, mostly around the age of 30 years. It is more common in women than in men, especially during the fertile period. Women with SLE are at higher risk for spontaneous abortions, intrauterine fetal death, preeclampsia and eclampsia, preterm delivery and intrauterine growth retardation (1).

Pregnant woman with systemic lupus erythematosus are at risk of lupus exacerbation during the pregnancy. Despite many studies, it is not possible to give a precise answer to the question of whether pregnancy induces an increased rate of lupus flare. Women suffering from SLE face higher risk of fetal losses, preterm births, or intrauterine growth retardations. However, if the pregnancy is properly planned and under interdisciplinary medical care, it is highly possible, besides exceptional cases, to give birth to a healthy child. Most authors do not recommend pregnancy in lupus patients (2). Sexual hormones, particularly estrogens, appear to play an important role in the development of SLE (3).

Nephritis is known to be one of the most serious complications of SLE and is a strong predictor of poor outcome. It is therefore important to inform women of the influence of lupus nephritis on pregnancy. Studies evaluating pregnancies for which conception occurred during active renal disease have reported flare rates of 48-62% in the pregnancies studied, whereas studies evaluating pregnancies initiated during remission of nephritis indicate flare rates between 7.4% and 32%. Thus, the natural history of renal disease in pregnancy remains to be elucidated (4).

CASE REPORT

A 27-year-old woman was diagnosed with systemic lupus erythematosus (SLE) six years before. She was admitted to the Department of Internal Medicine after being transferred from a Social Security Hospital. The patient's blood pressure was 140/100 mmHg, fever 38.2 °C, hemoglobin 8.4 g/dl, Hct 24.6%, white blood cell 6.5 x 10³ /qL, platelet 126 x 10³, BUN 69mg%, creatinine 1.6 mg%, Na 126 mEq/L, K 5.5 mEq/L, Ca 7.5mg%, blood glucose 84mg%, sedimentation 95 l/h, and CRP 57. She presented with severe dyspnea from acute left heart failure, tachycardia, polyarthrititis, and itchy/painful ulcerations between the fingers. Positive anti-nuclear antibody (ANA) and anti-double-stranded DNA (anti-ds DNA) antibody were determined. There was proteinuria (+++), hematuria (+++). Echocardiography showed pericardial effusion (Figure 1). A chest X-ray showed massive pulmonary congestion (Figure 2). She was a primigravida in the 27th week of gestation. No information was available about her antenatal examination. With these findings, she was transferred to the Nephrology Department. Initially left heart failure was treated with diuretics and intravenous afterload reduction. Albumin was given. After one day

¹ Department of Family Physician, Meram Medical Faculty, University of Selcuk, Konya, TURKIYE

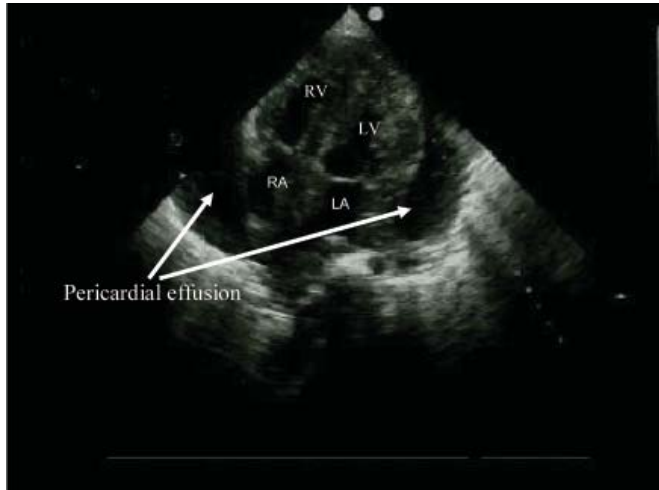


Figure 1: Echocardiography of the pregnant woman with SLE complicated by pericardial effusion.

her contractions started, her cervical dilatation was 4 cm, and the fetus was in a breech presentation. Cesarean section was performed due to preeclampsia, and a female baby was born. The birth weight of the baby was 900 g. Three units of erythrocyte suspension and fresh frozen plasma were given. Two days after birth, hemodialysis was performed due to oliguria and hyperkalemia. Two hours later, she died due to cardiopulmonary arrest.

CONCLUSION

Systemic lupus erythematosus (SLE) is an autoimmune disease that affects primarily women, commonly in their reproductive years, but does not influence fertility. For these reasons, the clinician has often to face many problems related to pregnancy in patients with SLE including the influence of SLE on fetal outcome and that of pregnancy on SLE. Early reports emphasized a high fatal and maternal risk, in particular in patients with lupus nephritis. However, in the same period the prognosis of lupus nephritis was poor, and so it was difficult to know whether pregnancy actually influenced the prognosis of the disease. More recent prospective studies indicate that pregnancy is safe for the majority of mothers if it is planned when SLE is quiescent. Instead, although fetal risk has been progressively reduced in the last 40 years, it continues to be higher than that occurring in pregnancies of healthy women. In particular, the presence of antiphospholipid antibodies considerably worsens the fetal outcome (5).

This paper is a case report of a pregnant woman with SLE complicated by preeclampsia and nephritis. In our patient, postgestational lupus flare up was noted. Risk factors included lower serum albumin, elevated serum ANA and anti-ds DNA antibody, proteinuria, pericardial effusion, massive pulmonary congestion, and hypertension. Thus, our patient had many risk factors for the development of preeclampsia. Our review of the literature revealed many similar cases (1-9). In conclusion, our patient died because of preeclampsia with acute heart failure as the primary manifestation of SLE and insufficient antenatal examination.

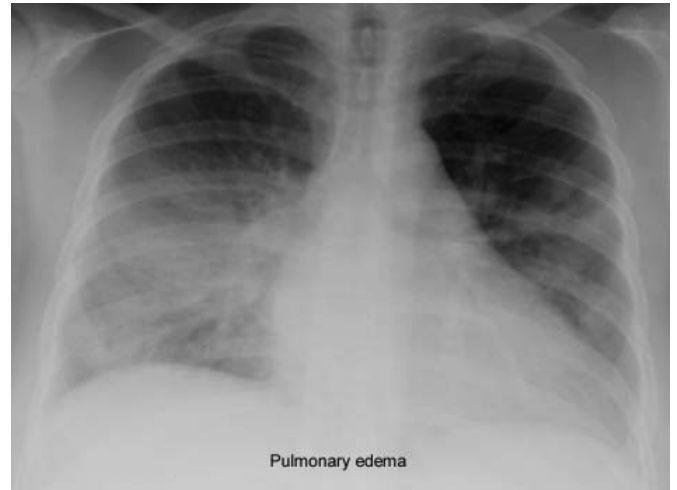


Figure 2: Roentgenogram of the chest of the pregnant woman with SLE complicated by pulmonary edema.

Correspondence Address

Ruhusen Kutlu

Department of Family Physician, Meram Medical Faculty,
University of Selcuk, Konya, TURKIYE

Tel: 0-332- 223 66 01 Fax: 223 61 81

E-mail: ruhuse@yahoo.com

REFERENCES

1. Radeka G, Novakov-Mikic A, Mitic I. Systemic lupus erythema tosus in pregnancy--case report. *Med Pregl.* 2005 May-Jun; 58(5-6): 301-307.
2. Sadowska A. [Pregnancy in women with systemic lupus erythematosus (SLE)] *Przegl Lek.* 2005; 62(1): 61-64.
3. Vanini G, Chizzolini C. [Systemic lupus erythematosus (SLE): sexual hormones, contraception and pregnancy] *Rev Med Suisse.* 2005 Apr 13; 1(15): 991-4. Review.
4. Tandon A, Ibanez D, Gladman DD, Urowitz MB. The effect of pregnancy on lupus nephritis. *Arthritis Rheum.* 2004 Dec; 50(12): 3941-3946
5. Moroni G, Ponticelli C. Pregnancy after lupus nephritis. *Lupus.* 2005; 14(1): 89-94.
6. Molad Y, Borkowski T, Monselise A, Ben-Haroush A, Sulkes J, Hod M, Feldberg D, Bar J. Maternal and fetal outcome of lupus pregnancy: a prospective study of 29 pregnancies. *Lupus.* 2005; 14(2): 145-151.
7. Yang CH, Chen JY, Lee SC, Luo SF. Successful preventive treatment of congenital heart block during pregnancy in a woman with systemic lupus erythematosus and anti-Sjogren's syndrome A/Ro antibody. *J Microbiol Immunol Infect.* 2005 Oct; 38(5): 365-369.
8. Egerman RS, Ramsey RD, Kao LW, Bringman JJ, Bush AJ, Wan JY. Hypertensive disease in pregnancies complicated by systemic lupus erythematosus. *Am J Obstet Gynecol.* 2005 Nov; 193(5): 1676-1679.
9. Hildbrand P, Eigenmann C, Gugger M, Marti HP, Hullin R. Preeclampsia with acute heart failure postpartum as primary manifestation of systemic lupus erythematosus. *Eur J Heart Fail.* 2005 Oct; 7(6): 1057-1058.