

# GARDNER DIAMOND SYNDROME

Esra ADIŞEN, Fulya KARACA, Mehmet Ali GÜRER

## ABSTRACT

Gardner-Diamond syndrome is a condition, usually occurring in women, in which bruising occurs easily with resulting ecchymoses, causing pain and tenderness in the affected skin areas. Psychiatric problems and the autoreactivity of the patients to their own blood are well known features of the disease, but the exact cause remains unknown. Herein we report a patient with characteristic features of this syndrome and want to emphasize the necessity of awareness of the disease in the elderly population so as to avoid unnecessary investigations.

**Key Words:** Autoerythrocyte Sensitization Syndrome, Episodic Ecchymoses, Purpura.

## GARDNER DIAMOND SENDROMU

### ÖZ

Gardner Diamond Sendromu sıklıkla kadınlarda ortaya çıkan, etkilenen bölgelerde ağrıya ve hassasiyete yol açan, kolay çürük oluşması ve ekimoz gelişmesi ile karakterize olan bir durumdur. Psikiyatrik problemler ve hastaların kendi kanlarına otoreaktivite göstermeleri hastalığın iyi bilinen özellikleridir ancak hastalığın kesin nedeni halen bilinmemektedir. Biz burada bu sendromun karakteristik özelliklerini bulunduran bir olguyu rapor ederek yaşlı popülasyonda gereksiz araştırmalardan kaçınmak için bu sendromun bilinmesi gerektiğini vurgulamak istemekteyiz.

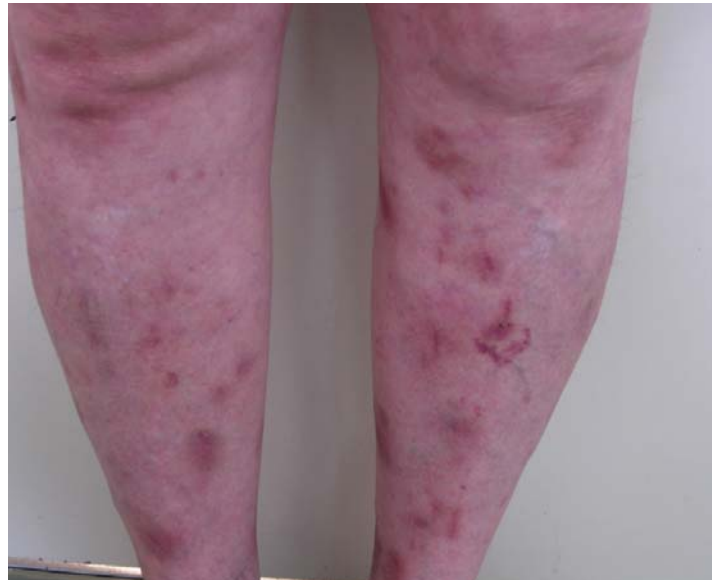**Anahtar Kelimeler:** otoeritrosit sensitizasyon sendromu, epizodik ekimozlar, purpura.

## INTRODUCTION

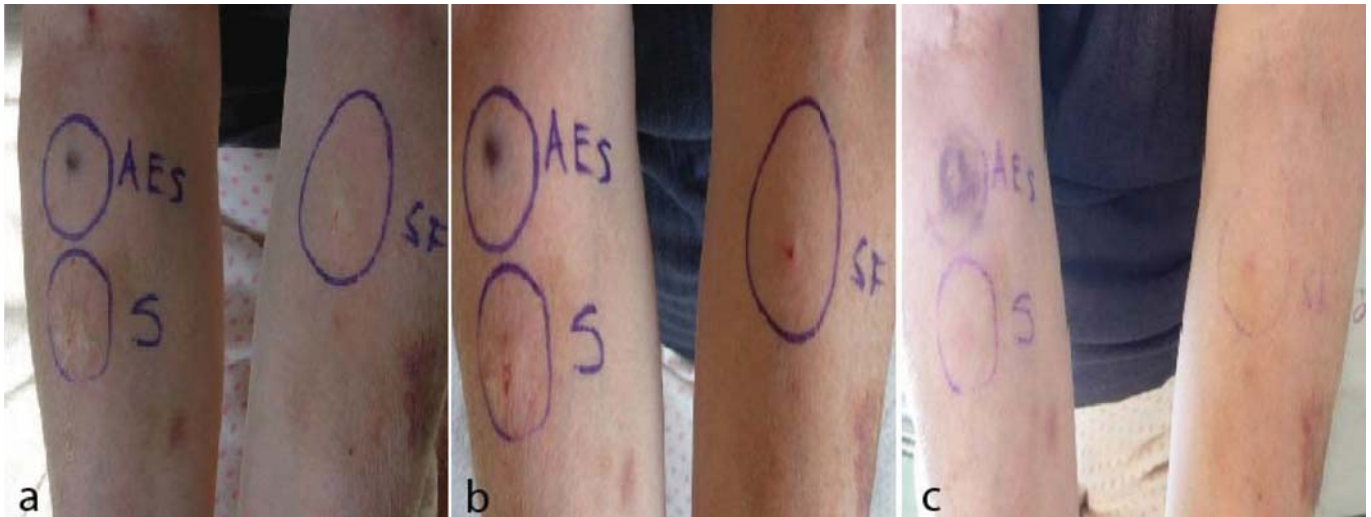
Autoerythrocyte sensitization syndrome was firstly described by Gardner and Diamond in 1955 in four women with painful bruising.<sup>1</sup> Since then, over 100 cases have been reported in the literature.<sup>2-10</sup> The disease affects women and cases have been reported in patients between 13 and 66 years old.<sup>3,4</sup> Rare cases in males have also been reported.<sup>5</sup> The syndrome is characterized by recurrent, painful spontaneous bruising of the skin often precipitated by emotional stress.<sup>2</sup> We report a patient with characteristic features of this syndrome and emphasize the necessity of awareness of the disease in the elderly population in order to avoid unnecessary investigations.

## CASE REPORT

A 63-year-old woman presented with a two-year history of recurrent episodes of painful ecchymotic lesions over the anterior aspects of the arms and legs. The lesions were sudden in onset, recurring every few weeks, and not associated with injury, self harm, insect bites, or intake of drugs. The patient's major complaint was pruritus. The onset of lesions was usually preceded by intense pruritus, tingling, pain, and tenderness in a localized area. The patient had received various kinds of antihistamines, and topical and oral corticosteroids without any benefit. Her past medical history included depression and panic attacks. She had received many drugs for these diseases. Lastly, alprazolam was suggested but she had given up a month before. The patient's own theory about the reason for the occurrence of the lesions was stress. A cutaneous examination revealed ecchymoses varying in size from 1 to 3 cm, excoriations,



**Figure 1:** Multiple ecchymoses on the lower legs.



**Figure 2:** Autoerythrocyte sensitization test. **a:** at 30 min, **b:** at 24 h, **c:** at 48 h. AES: Autologous erythrocytes of the patient, S: serum of the patient, SF: 0.9% NaCl.

and erosions on the anterior aspects of the upper and lower extremities. Her face, back, and chest were spared. Laboratory examinations including complete blood cell count with differential, chemistry profile, electrolytes, and platelet counts, and platelet aggregation tests were performed and all were within the normal ranges. Coagulation system parameters such as prothrombin time, partial thromboplastin time, and D-dimers had normal values. The erythrocyte sedimentation rate was 30 mm/h, and C reactive protein was negative. Antinuclear antibodies, antidouble-stranded DNA, anticardiolipin antibodies, and Coomb's tests were negative. A psychiatric consultation revealed the diagnosis of depression, and treatment with sertraline was started. After the initial examination, our possible diagnoses were steroid ecchymoses, Gardner-Diamond syndrome, and factitious purpura. Therefore, we detailed the anamnesis, and learnt that the patient had applied topical steroids only to her arms. As there were lesions on the lower legs, the lesions could not be related to steroid use. The skin lesions were covered for 24 h with occlusion bandages and were checked every day. New lesions continued to occur both inside and outside of the occlusion area. This observation suggested that the disease was not factitious purpura. We decided to perform an autoerythrocyte sensitization test. Autologous erythrocytes of the patient, serum, and 0.9% NaCl were injected intradermally into the inner aspect of the forearm. Readings were performed at 30 min, 24 h, and 48 h. While the occurrence of an ecchymotic lesion was observed at the autologous erythrocyte injected site at 24 h and 48 h, no reaction was seen at the serum or 0.9% NaCl injected site (figure 2a and 2b). A diagnosis of Gardner-Diamond syndrome was established. The patient was discharged from the hospital under psychiatric care. Sertraline provided relief in her condition, and the skin lesions continued to improve with supportive medical care during the follow up of 4 weeks.

## DISCUSSION

Gardner-Diamond syndrome is a condition, usually occurring in women, in which bruising occurs easily, with the resulting ecchymoses causing pain and tenderness in the affected skin areas. There are some controversies about the origin of the disease, but the close connection with psychiatric problems and the autoreactivity of the patients to their own blood are well described.<sup>2</sup>

The first hypothesis was based on the observation that these patients had an abnormal reaction to their own extravasated red cells.<sup>2</sup> Later, some authors reported abnormal platelet responses during platelet aggregation studies<sup>3</sup> and the role of the hematological and immunological abnormalities in the etiopathogenesis of the disease has been begun to be considered. Other reported precipitant factors are trauma and foreign body reaction.<sup>10</sup>

There have been no established diagnostic criteria for the disease to date. Ingber et al.<sup>5</sup> suggested considering a typical clinical presentation, longstanding clinical history, and a positive skin test with the patient's blood when establishing the diagnosis of the disease. Others stressed the existence of a psychiatric component causing predisposition to the disease and named the disease using the term "psychogenic purpura".<sup>6</sup> The majority of patients describe an association with severe emotional stress or psychological associations such as conversion reaction, hysterical or masochistic personality, depression, anxiety, difficulty in dealing with hostile feelings, or religious stigmatization.<sup>7,8,11</sup> We think that the psychological condition of our patient had an effect on the course of the disease, particularly on the occurrence of the acute episodes of the disease. Our patient had problems with her children and had had depressive symptoms for a long time. She was sure that the skin condition had begun soon after the first episode of depression. In addition, she had observed that the lesions occurred more frequently when she was upset. Probably the most challenging step in the diagnosis of the disease is to decide whether the clinical picture presents a sign of an asso-

ciating systemic disorder or not. In most cases, the patient's dramatic appearance frightens physicians unfamiliar with the condition and causes inappropriate laboratory examinations. Clinical suspicion is needed to consider the diagnosis of Gardner-Diamond syndrome.

There is no established treatment for the condition. Patients' responses to various treatment modalities are different and most of the treatments are not successful in providing permanent relief. The only known effective therapy is to find out the triggering factor and to eliminate it.<sup>9,10</sup> Albumin infusions, antibiotics, anticoagulants, antihistaminics, busulphan, chloroquine, corticosteroids, cyproheptadine, desensitization with red cell extracts, hormones, immunosuppressive agents, meperidine, pentoxifylline, plasmapheresis, splenectomy, and vitamin C are reported treatments for the disease.<sup>2</sup> Some patients may be best treated in collaboration with a psychiatrist.

Our patient had the characteristic features of the syndrome. This rare and particularly benign cause of purpura should be remembered in the differential diagnosis of episodic purpura located on the extremities in order to avoid unnecessary investigations.

*Correspondence Adres*

*Esra ADIŞEN*

*Gazi University Faculty of Medicine Department of Dermatology  
06500 Beşevler, Ankara TURKEY*

*Phone: 0 312 202 61 29*

*Fax: 0 312 212 90 18*

*E-mail: eozsoy@gazi.edu.tr*

## REFERENCES

1. Gardner FH, Diamond LK. Autoerythrocyte sensitization: a form of purpura producing painful bruising following autosensitization to red blood cells in certain women. *Blood* 1995; 10: 675-690.
2. Yun YY, Muir J. Periodic painful purpura: Fact or factitious? *Australas J Dermatol* 2004; 45(1): 58-63.
3. Puetz J, Fete T, Platelet function disorder in Gardner-Diamond syndrome: a case report and review of the literature. *J Pediatr Hematol Oncol* 2005; 27(6): 323-325.
4. Regazzini R, Malagoli PG, Zerbinati N, De Filippi C, Serra F, Donadini A. Diamond-Gardner syndrome: a case report. *Pediatr Dermatol* 1998; 15: 43-45.
5. Ingber A, Alcalay J, Feuerman EJ. Autoerythrocyte sensitization (Gardner-Diamond syndrome) in men: a case report and review of the literature. *Postgrad Med J* 1985; 61: 823-826.
6. Ratnoff OD, Agle DP. Psychogenic purpura: a re-evaluation of the syndrome of autoerythrocyte sensitization. *Medicine (Baltimore)*. 1968; 47(6): 475-500.
7. Uthman IW, Moukarbel GV, Salman SM, Salem ZM, Taher AT, Khalil IM. Autoerythrocyte sensitization (Gardner-Diamond) syndrome. *Eur J Haematol* 2000; 65: 144-147.
8. Gundogar D, Yuksel Basak P, Baysal Akkaya V, Akarsu O. Autoerythrocyte sensitization syndrome associated with grief complications. *J Dermatol* 2006; 33(3): 211-214.
9. Siddi GM, Montesu MA. Gardner-Diamond syndrome. *J Eur Acad Dermatol Venereol* 2006; 20(6): 736-737.
10. Grossman RA. Autoerythrocyte sensitization worsened by a copper-containing IUD. *Obstet Gynecol* 1987; 70: 526-528. Gupta AM, Gupta AK. Psychodermatology: An update. *J Am Acad Dermatol* 1996; 6: 34.