

## SCROTAL ABSCESS IN A NEWBORN: REPORT OF A CASE

M. Emin BOLEKEN, Mete KAYA, Turan KANMAZ, Selçuk YÜCESAN

We report a case of scrotal abscess following a colostomy operation in a newborn with an imperforate anus. The presentation, evaluation and pathophysiology are discussed.

**Key Words:** Scrotal abscess, colostomy, newborn.

### YENİDOĞANDA EKROTAL APSE: OLGU SUNUMU

İmperfore anüs nedeniyle kolostomi ameliyatı yapılan bir yenidoğanda gelişen skrotal abse olgusu sunuldu. Bulgular, değerlendirme ve patofizyoloji tartışıldı.

**Anahtar Kelimeler:** Skrotal abse, kolostomi, yenidoğan.

### INTRODUCTION

Scrotal abscess is uncommon in the neonatal period and is extremely rare secondary to abdominal procedures. We report a case of scrotal abscess in a 2-day-old newborn with high-level imperforate anus, 5 days after a colostomy operation.

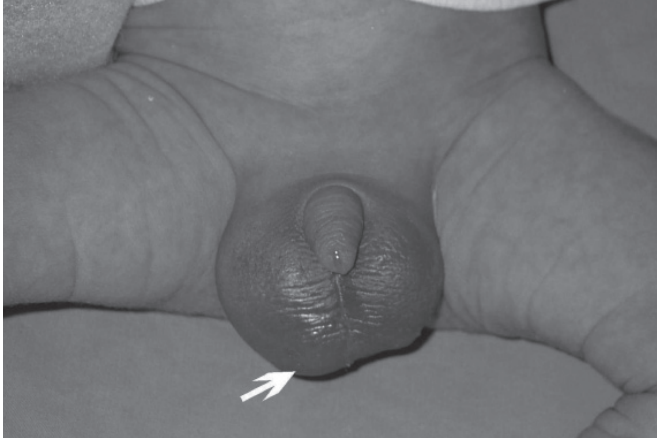
### CASE REPORT

A 2-day-old neonate born by spontaneous vaginal delivery presented with vomiting, abdominal distension and failure to pass meconium. On physical examination, we detected an imperforate anus with no cutaneous fistula. Laboratory data revealed a white blood cell count of 13,500/mm<sup>3</sup> and normal urinalysis. Radiologically, the erect plain abdominal radiograph showed multiple air fluid levels, the cross-table lateral film with the patient in the prone position represented a high anomaly, and no recto-urinary fistula was present on the urethrogram. After the initiation of antibiotic therapy (ampicillin and gentamicin), the patient underwent right transverse loop colostomy without abdominal exploration. On the third postoperative day, the colostomy functioned, and then on day 5 we observed right scrotal swelling with skin erythema and irritability when it was touched, despite body temperature being normal (Figure 1). Laboratory evaluations included a white blood count of 15,000/mm<sup>3</sup> and normal urinalysis. The abdominal ultrasound investigation was normal, but color Doppler ultrasound revealed a right paratesticular hydrocele fluid with debris and high flow within around the right testicle, suggesting the possibility of an infectious disease. Approximately 5 cc of purulent material was drained via a scrotal incision where the skin was thin, and the wound was irrigated. Culture taken from the scrotal abscess yielded *Escherichia coli*. He was discharged from hospital on postoperative day 12. The induration had completely resolved five weeks postoperatively; the right testis was normal in size and color Doppler ultrasound demonstrated good flow.

### DISCUSSION

A colostomy usually is recommended in the neonatal period for the management of patients with anorectal anomalies, but it has been reported that it is a potentially morbid condition in neonates and is prone to complications (1). The most common complications include colostomy prolapse, colostomy retraction, skin dehiscence and excoriation, intestinal obstruction, and stomal ulceration and bleeding.

Scrotal abscess was not reported previously in patients with anorectal malformations who underwent colostomy. Oguzkurt et al. (2) suggested that abnormalities of the vas deferens with reflux of urine into the vas deferens predispose children with anorectal



**Figure 1:** Scrotal swelling with skin erythema and localized thinned scrotal skin (arrow) on postoperative day 5.

anomalies to epididymo-orchitis. In our patient, we did not find a recto-urinary fistula or urethrovasal reflux. Furthermore, urinalysis was not consistent with a urinary tract infection.

Scrotal abscess has been reported following abdominal operations (3, 4). Peritonitis developed and the infection spread to the scrotum via a patent processus vaginalis (PPV)—in other words—during abdominal operations, peritoneal fluid may be contaminated by enteric microorganisms and contaminated fluid may enter the PPV with resultant scrotal abscess formation. Indeed, a PPV had been found in some of these patients. Furthermore, a PPV has been estimated to be present in 80% to 95% of all male newborns (5). In our 2-day-old pa-

tient, scrotal abscess developed after an abdominal operation. Although we do not know whether a PPV was present in our patient, the culture taken from the abscess yielded *E. coli*, indicating an infectious origin in the abdominal cavity.

The present case displays a rare complication of colostomy and shows that scrotal abscess may develop by enteric microorganisms through PPV.

*Correspondence Address*

*M. Emin BOLEKEN, MD*

*Harran Üniversitesi Araştırma Uyg. Hast.*

*Çocuk Cerrahisi Anabilim Dalı Şanlıurfa, Turkey*

*Tel: 0(414) 314 11 70 Fax: 0(414) 3151181*

*E-mail: mboleken@yahoo.com*

## REFERENCES

1. Patwardhan N, Kiely EM, Drake DP, et al. Colostomy for anorectal anomalies: High incidence of complications. *J Pediatr Surg* 2001; 36: 795-798.
2. Oguzkurt P, Tanyel FC, Büyükpamukcu N. Acute scrotum due to epididymo-orchitis associated with vasal anomalies in children with anorectal malformations. *J Pediatr Surg* 1998; 33: 1834-1836.
3. Thakur A, Buchmiller T, Hiyama D, Shaw A, Atkinson J. Scrotal abscess following appendectomy. *Pediatr Surg Int* 2001; 17: 569-71.
4. Gan BS, Sweeney JP: An unusual complication of appendectomy. *J Pediatr Surg* 1994; 29: 1622.
5. Rowe MI, Lloyd DA: Inguinal hernia, in Welch KJ, Randolph JG, Rawitch MM, et al (eds): *Pediatric Surgery*. Chicago: Year Book Medical, 1986, p 779-93.