

ELECTROSURGERY: PITFALLS AND RECOMMENDATIONS

Yener DEMİRTAŞ, M. D., Sühan AYHAN, M. D.¹, Reha YAVUZER, M. D.¹, Osman LATİFOĞLU, M. D.¹, Cemalettin ÇELEBİ, M.D.¹

Purpose: In spite of the fact that the electrosurgical unit is the most frequently used energy source in the operating room, it is probably the one least understood by the operating room personnel, including the physicians. This study was performed to develop a conceptual understanding of some basic principles concerning the adept use of electrosurgery instruments.

Materials and Methods: We documented all electrosurgery injuries occurring in our operating rooms over the previous 20 months. We analyzed the injuries, and revealed causative factors and preventive measures to minimize these injuries.

Results: We encountered 12 electrosurgery injuries, six of which were glove bites suffered by the surgeons. Six of the injuries were different electrosurgery complications experienced by the patients, two of which were eventually fatal.

Conclusion: Electrosurgery injuries in the operating room are infrequent, but we think that the issue deserves attention, because basic electrosurgical principles are important for appropriate, effective and safe use of the instruments and the prevention of stray current injuries. It is recognized that simple precautions would sufficiently eradicate injuries caused by electrosurgery.

Key Words: Electrosurgery, cautery, injury, complication, glove bite, plate burn.

ELEKTROCERRAHI: TEHLİKELER VE ÖNERİLER

Amaç: Elektrocerrahi üniteler, ameliyathanelerde en sık kullanılan enerji kaynakları olmalarına karşın muhtemelen hem cerrahlar hem de diğer ameliyathane personeli tarafından en az anlaşılan cihazlardır. Bu çalışma, elektrocerrahi cihazlarının uygun kullanılabilmesi için bazı temel prensipleri ortaya koymak amacıyla yapılmıştır.

Gereç ve Yöntemler: Son 20 ayda ameliyathanelerimizde ortaya çıkan elektrocerrahi yaralanmalarının dökümünü çıkardık. Yaralanmaları inceledik, sebep olabilecek faktörleri gözden geçirdik ve bu yaralanmaları en aza indirmek için alınabilecek önlemleri belirledik.

Bulgular: On iki elektrocerrahi yaralanması tespit ettik, bunlardan altısı cerrahlarda meydana gelen eldiven yanıqlarıydı. Altı yaralanma hastaların başına gelen değişik elektrocerrahi komplikasyonlarıydı ve bunlardan ikisi ölümcüldü.

Sonuç: Ameliyathanelerde meydana gelen elektrocerrahi yaralanmaları seyrek olmakla birlikte konunun önemli olduğuna inanmaktayız. Çünkü cihazların uygun, etkili ve güvenli kullanımı ve kaçak akımlara bağlı yaralanmaların önlenmesi için temel elektrocerrahi prensipler önemlidir.

Anahtar Kelimeler: Elektrocerrahi, koter, yaralanma, komplikasyon, eldiven yanığı, plak yanığı.

PRIMUM NON NOCERE (FIRST DO NO HARM)

Hippocrates

Hippocrates was not the first, but was the strongest advocate of the cautery (to burn in Greek); modern electrosurgery generators or the so-called cautery devices were introduced in 1928 by Harvey Cushing, a neurosurgeon, and William T. Bovie, a physicist, who developed the system utilizing the principles invented by Hertz in 1886 (1-8). The use of this fool-proof hemostatic instrument became widespread year by year, assisting in the advancement of surgery, and today it is the most frequently used energy source in operating rooms worldwide as a major surgical element in all kinds of surgery (8-21). Indeed, the use of electrosurgery is now so common that education about the principles of this technology is considered superfluous (5,6,17). Although recently developed technology ensures that electrosurgery is performed in a safer manner, it has not reduced the significance of preventive measures that should be taken for the safety of the patient and the surgeon in electrosurgical practice. We describe the occurrence of tissue injuries in patients and surgeons during electrosurgery along with a review of basic electrosurgical principles intended to guide surgeons through appropriate, effective and safe electrosurgery applications.

BASIC PRINCIPLES

Alternating current (AC) is the type of electricity found in household electrical outlets, where the circuit reverses about 60 times per second, or 60 Hertz (Hz). Electrosurgery units (ESU) convert this current to frequencies in a range close to AM radio station transmissions, 350 kHz to 4 MHz, referred to as radiofrequency (RF) (5-8,15,18-20). When AC lower than 100 kHz is applied to human tissue, neuromuscular stimulation effects or "muscle twitching" known as Faradic effects occur (1,5,6). Currently, very high frequency generators (3-4 MHz) allowing for a convenient "antenna" grounding plate called RF units are quite popular for office surgery (6,15,22,23).

Bipolar Electrosurgery

Monopolar and bipolar electrosurgery are quite different, not only in terms of the pathway the current follows, but also in terms of their potentials for complications. In bipolar electrosurgery, both of the electrodes are in direct contact with the target tissue and the current does not need to pass through the entire body to get back to the other electrode. It follows the shortest pathway with least resistance, that is, the tissue grasped between two poles where the desired coagulation effect occurs. Bipolar electrosurgery is definitely a much safer modality, and almost all of the complications attributed to electrosurgery are related to the use of the monopolar variety. The common belief, that bipolar modality

is useful when performing delicate procedures but not feasible in common surgical practice (19), is outdated. Although new instrumentation allows for bipolar cutting and dissection with bipolar scissors, monopolar electrosurgery is still the most widely preferred modality (5,6,8,13,16,19,24-27).

Monopolar Electrosurgery

The monopolar system is composed of an active electrode that is in contact with the target tissue for cutting or coagulation, and a dispersive electrode (neutral electrode, ground pad, cautery plate, patient electrode) where the current leaves the body. At the active electrode site, temperature markedly rises to over 1000 °C, already falling steeply in the immediate vicinity of the point of contact and amounting to a difference in temperature of still only 1 °C at a tissue depth of 1 cm (1,15,28). "Cut", "blended" and "coag" modes are used to adjust the hemostatic effects of the applied current. Regarding the wound healing and electrosurgical safety issues, low voltage "cut" is the best, high voltage "coag" is the worst and, as the name implies, "blended" modes are somewhere in between (8,13,15,18,20,23,25).

It is not the direction of current flow that determines the outcome, i.e. cut or coagulation at the active electrode site and nothing at the dispersive electrode. You could change the connections to the machine and still get the same effect. The only difference is in the surface contact areas of the electrodes (1,5-7,9,23,28-31). The dispersive electrode does just what its name implies, disperses the energy. As low an energy density as possible will be achieved on discharging the current via the neutral electrode with as large a surface area in contact with the body. If, for any reason, the surface contact area gets smaller, the electrosurgical current always has the potential to intensify in this region and cause a burn. Some units incorporate safety systems to sense the contact area of the ground pad and warn the surgeon.

MATERIALS and METHODS

All electrosurgery injuries encountered in our operating rooms over the previous 20 months were determined. We analyzed these accidents and tried to reveal causative factors insofar as it was possible. The specific origin of these complications and a thorough investigation of errors are compounded by several factors and sometimes prove impossible. We considered the probable scenarios and endeavored to set forth scientific opinions, because a flagrante delicto was frequently not achievable, except for the glove bites. The reason is obvious; surgeons are conscious to react to an injury, but patients are not due to general anesthesia. Burns were not usually detected immediately after surgery in the operating theater but sometimes days later. Moreover, they were not always recognized as electrosurgery complications at first sight and some were wrongly diagnosed as bed sores or allergic reactions to the disinfectant solutions. Following a comprehensive review of the literature, we held interviews with the electrosurgery generator manufacturers to further clarify the mechanisms of these accidents. Finally, preventive measures to minimize these injuries are designated and presented in a concise manner.

RESULTS and CASE REPORTS

Of the 12 electrosurgery injuries detected, six were glove bites suffered by the surgeons and the remaining six were different electrosurgery complications experienced by the patients.

Case 1: A 27-year-old man complained of pain in his right chest immediately after craniofacial surgery that lasted 3 hours. Upon inspection, a 4 x 6 cm lesion of a second-degree burn was detected (Fig. 1). Desiccation with monopolar electrosurgery on high power "coag" mode was used in this patient for hemostasis during bicoronal incision of the scalp. The localization and the shape of the lesion resembled an alternative site burn caused by an ECG monitor electrode. Actually, it is impossible to confirm the real origin of such a wound, but the most probable scenario is the induction of a stray current by a damaged electrode, possibly because of wetness. The sticky electrodes used today are definitely safer than the historical pinned ones; nevertheless, they are not free of risk, and monitoring electrodes should not be placed along the electrosurgical pathway (6,32,35). If the surgical site is in the head, for example, habitual application of the neutral electrode to the thigh is not appropriate. It should rather be applied to the muscular region of the arm (preferably the right one, far from the heart) to keep the electrodes in the chest away from the path of the current. Theoretically, it is likely that any conductor that is in contact with the patient and the ground (a wet surgical dressing) will act as a short-cut for the high voltage "coag" current and cause a skin burn. Although it was found to be problem free retrospectively, any problem in the ECG monitor would have facilitated this kind of incident.

Case 2: A 42-year-old, quite tall, male patient was diagnosed with third degree burns to both heels (Fig. 2) following long (seven hours) multi-department surgery after a traffic accident. Hemostasis was exclusively achieved by monopolar

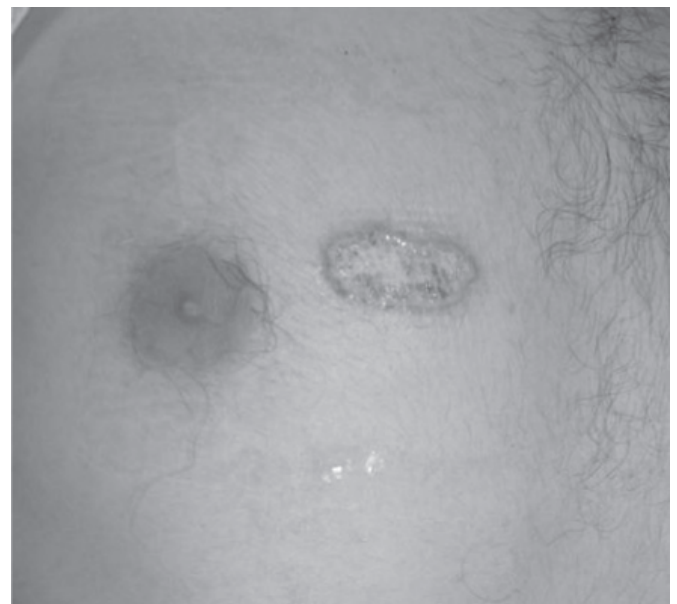


Figure 1: Second-degree alternative site burn on the chest of the patient.

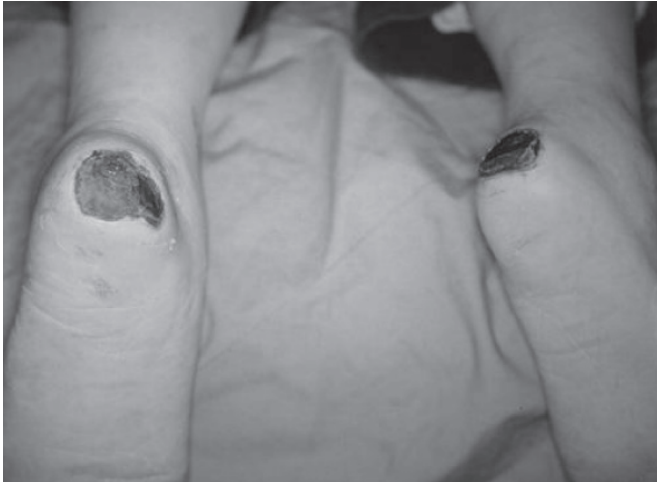

Figure 2: Third-degree burns on the heels of the patient.

lar “coag” current during the operation. This injury was also partially attributed to an alternative site burn, considering the height of the patient and the length of the procedure. The patient’s heels presumably extended beyond the insulating rubber covering the operating table and were touching the metallic part throughout the surgery, resulting in a deep burn. The ischemia caused by the continuous pressure almost certainly alleviated the injury, but we could not consider these pressure sores as the injury was detected the day after surgery. The period of 24 hours was thought to be too short to result in such a deep injury. Wetness of the surgical dressing and electrodes must be avoided and possible problems in the monitor or any conductive, grounded equipment that is in contact with the patient must be suspected, taken seriously and checked out routinely to prevent such accidents in cases one and two.

Case 3: A 66-year-old female patient was referred to our department three days after cardiovascular by-pass surgery in

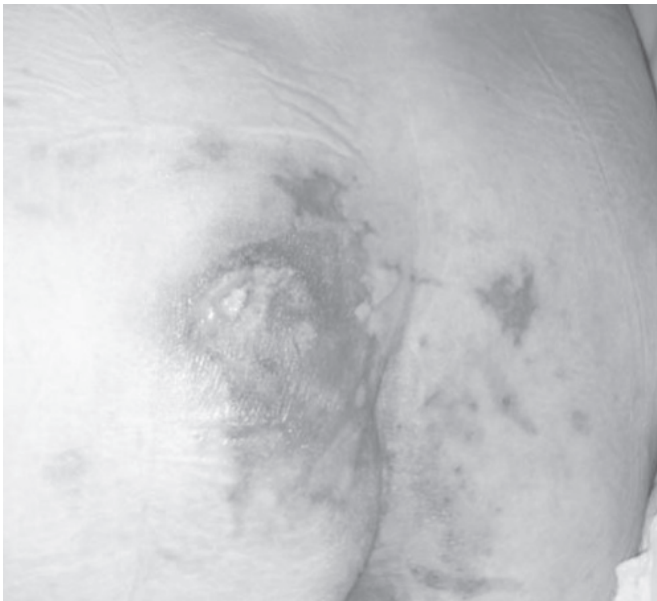

Figure 3: Second-degree wound on the buttock.

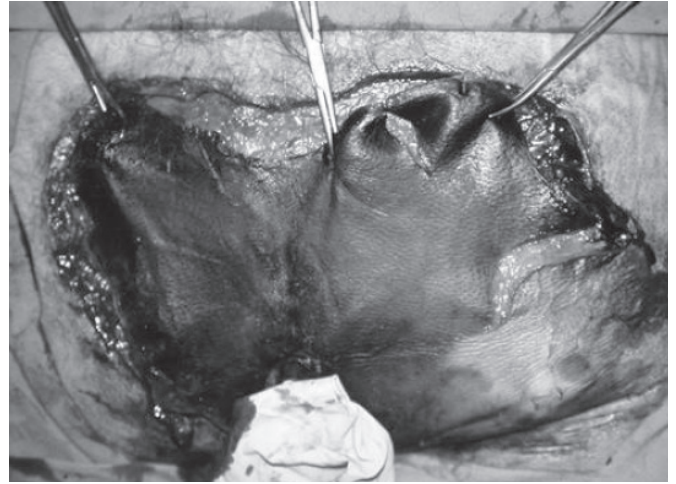


Figure 4: Deep third-degree burn covering the sacro-gluteal region. Condition three days after surgery.

which hemostasis had been achieved with monopolar electro-surgery. She had a second-degree lesion on her left buttock (Fig. 3), which was not present before the operation and was noticed the day after it. The lesion healed uneventfully in two weeks.

Case 4: A deep third-degree lesion covering the entire sacro-gluteal region of a 69-year-old male patient (Fig. 4) was noticed three days after long-lasting cardiovascular by-pass surgery, in which monopolar electro-surgery had been exclusively utilized. Although adequate debridement and several daily dressing changes were performed, the patient died from systemic septicemia three weeks after the surgery. These kinds of injuries are occasionally encountered after long-lasting cardiovascular procedures and monopolar electro-surgery; the high voltage “coag” mode is usually the scapegoat. The skin injuries are not necessarily located under the grounding pad or near the monitoring electrodes and the causes of these wounds

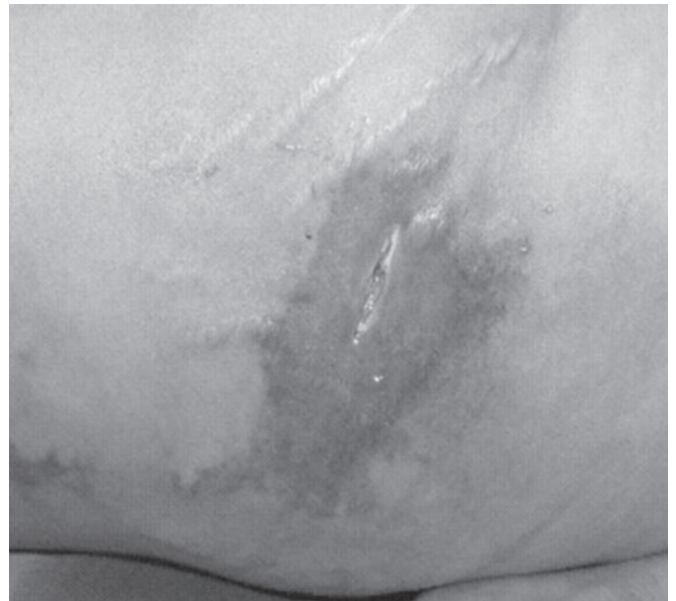
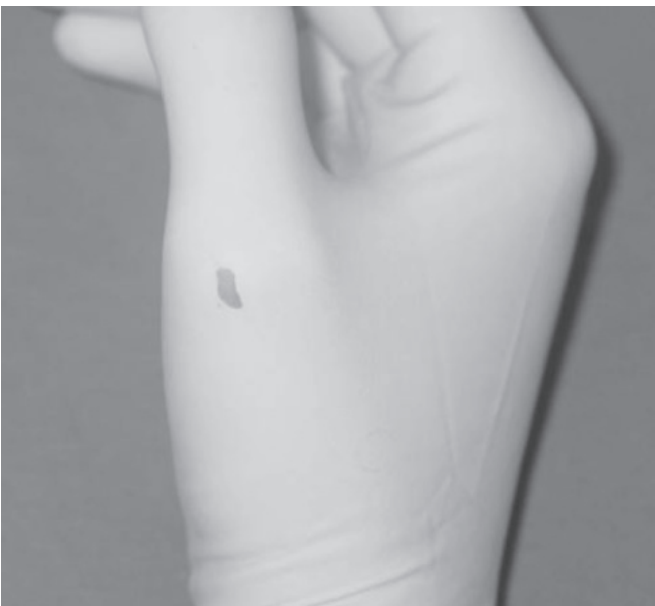


Figure 5: Retrograde necrotizing soft tissue infection secondary to bowel perforation as a complication of monopolar laparoscopic electro-surgery.

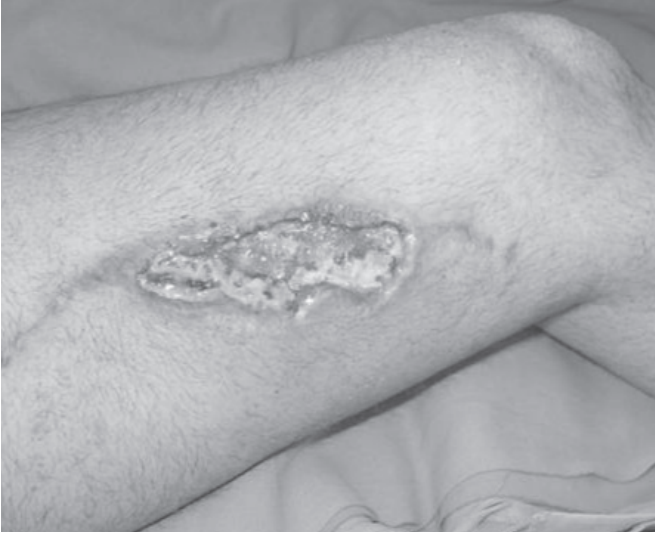

Figure 6: A wound on the thigh caused by a partially detached grounding pad.

may be a combination of two or more factors rather than just one (36). The sacral region is a common site of electrosurgery-induced burns, and physiological as well as electro-mechanical factors are generally involved (28). Circulation in the sacral region is poor compared with that in other areas of the body, especially owing to contact pressure when the patient is lying in the supine position. In electrosurgery, impaired circulation means a reduction in the discharge of heat generated in tissue by the current flow (28). It cannot be established whether these accidents were due to excessive moistening of the operating sites, to blood and rinsing fluid that seeped under the patients or to urine from a leaking catheter. Blankets that are frequently used in cardiovascular operations could also facilitate these injuries and patients must be kept a suitable distance from the heater and the length of time that heating blankets are used for must be shortened (37).



Case 5: A 40-year-old female was examined because of a skin color change on her right flank four days after a laparoscopic salpingo-oophorectomy (Fig. 5). She was diagnosed with a necrotizing soft tissue infection after a “finger test” and urgent debridement was performed. Exploration of the abdomen revealed the etiology; there was a perforation in the sigmoid colon. In spite of colostomy and adequate debridement, the patient was lost eventually. Histological evaluation of the resected bowel segment confirmed the thermal injury; it was a monopolar electrosurgery complication. Thermal injury to bowel during laparoscopy or hysteroscopy is a rare but serious complication of electrosurgery and a delay in the diagnosis is mostly fatal, as in our patient. Among the cases reported in the literature (38-43), bowel injury progressing to retrograde necrotizing soft tissue infection of the abdominal wall has not been encountered before. Laparoscopic electrosurgery is an entirely unique application in which the risk of unintended tissue injury is high if insufficient caution is exercised. Personnel should take special precautions when using the ESU during endoscopic and laparoscopic procedures (21). Preference for the bipolar system instead of the monopolar one will definitely eliminate the largest part of the threat.

Case 6: A 35-year-old male patient presented with a plate burn on his left thigh (Fig. 6). The lesion occurred during femoral by-pass surgery performed in the right lower extremity one month before. An early attempt to revise the wound had been unsuccessful and he was referred to our department. The injury was supposed to be the result of a partially detached neutral electrode. Surgical studies have demonstrated that the greatest risk for inducing grounding burns is careless application, caused in particular by excess hair or poor adhesion of the grounding pad. Approximately 500 electrosurgery related burns are reported to the FDA yearly (44). Most documented burns caused by electrosurgery occurred due to inadequate site preparation, such as improper shaving of the area underneath the grounding pad or its application to moist, oily skin (10,1

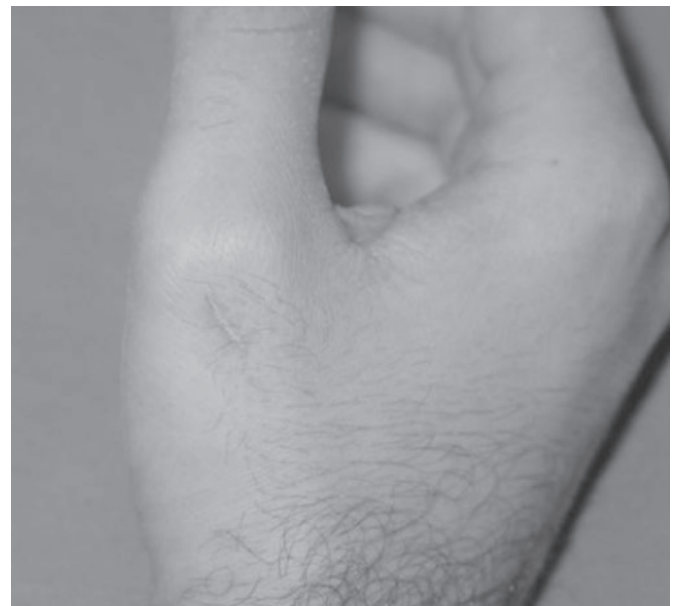

Figure 7: A glove bite encountered during electrosurgical desiccation utilizing high-power “coag” mode. High voltage current penetrated the glove and burned the skin.

5,19,23,31,35,45,46). A patient burn in the area of the neutral electrode is a factor of time and how small the area gets.

Case 7: Monopolar surgery in “coag” mode at 120 W was being utilized during an abdominal surgery. The surgeon, who was handling the active electrode, accidentally touched the hand of the assistant with it gently as the current was on. This high-powered current rent the glove and caused a second-degree burn (Fig. 7). That is a typical “direct coupling” injury, but direct contact is not essential for a glove burn; a stray current of high voltage “coag” mode has the capacity to burn you from a distance of several centimeters. The higher driving force (voltage for electricity) allows sparks to jump farther in air. This is seen with the long sparking when fulgurating tissue in high-voltage “coag” mode (5-7). The hole you see in the glove was not there when the current first jumped, it was rather created by the heat of the spark. Electricity can jump right through insulators if given enough driving force. For example, voltage levels in a bolt of lightning are capable of jumping through an insulator of about one mile in thickness (6). To the best of our knowledge, no data exist in the literature on viral transmission via these glove perforations.

DISCUSSION

Appropriate and efficient use of electrosurgery is directly related to length of operation, blood loss, infection, pain and wound healing (14-16,19,26,49,51), and electrical burns as complications of electrosurgery are the most common (60%) (52) and important causes of operation-related skin injuries detected in patients, as well as in surgeons (5-7,10,15,17,19,21-23,33,35,40,45,53,54). The potential explosion of anesthetic and endogenous intestinal gases, the induction of arrhythmias and the effect on pacemakers or internal probes pose additional risks in electrosurgery (6,9,10,15,19,21,28,35,53,55-58). Although the literature is full of studies on the principles and complications of electrosurgery with the aim of safer and more efficient practice, the plastic surgery literature seems to be lacking in this respect. We think that this is a potential drawback for our theoretical platform, and deserves critical and consistent apprehension. Plastic surgeons, well known as being respectful to tissue, are ultimately involved in electrosurgery complications at least in the reconstruction stage. Yet, prevention is the best approach, and the hazards of electrosurgery are best avoided by having a working knowledge of the basic principles (6).

A recent study by Sudhindra et al. revealed that most surgeons do not personally supervise the application of the patient's neutral plate during monopolar electrosurgery (8). Their study also demonstrated significant levels of ignorance, regardless of seniority or specialty, about this potentially dangerous operating theater equipment. Greater collaboration among theater staff is of major significance in avoiding electrosurgery complications. Such cooperation calls for adequate experience in dealing with the technical equipment and an awareness of what can go wrong during electrosurgery (8,15,17,28).

The surge of interest in other forms of energies, such as laser or ultrasound, was not sufficient to lead to the replacement of the relatively simple, cost-effective and user-friendly electrosurgery units in the operating rooms (5,6,19). Furthermore, the newly equipped ESUs are more complicated than their older counterparts and require in-service training before being put into practice, which is already offered by certain manufacturers.

Here are some practical hints for avoiding electrosurgery complications:

- Personnel selecting the ESU and accessories for purchase or use should make decisions chiefly based on safety features (21).
- The ESU should be used according to the manufacturers' written instructions.
- The patient's metal jewelry should be removed if it is within the path of the current (during monopolar electrosurgery).
- If securing the active electrode cord to the drapes, plastic or another nonconductive material should be used, and the cord should not be coiled.
- The active electrode should be placed in a clean, dry, well-insulated safety holster when not in use.
- Dispersive electrodes should be an appropriate size for the patient (e.g., pediatric, adult) and not altered (e.g., cut, folded).
- Neutral electrodes should not be applied to scar tissue, over bony protuberances, to hairy surfaces, to metal implants, to fatty body regions (21,46), or to areas distal to tourniquets and tattoos, many of which contain metallic dyes.
- They should rather be placed on clean, dry skin, over a large, well-perfused muscle mass on the surgical side, and as close to the surgical site as practical.
- Do not allow the surface of the electrode to come in contact with alcohol, soap or any fluid.
- Check that the return electrode is entirely in contact with the skin if the patient is moved.
- Currently available “Return Electrode Monitoring” (5), “Neutral Electrode Monitoring” (47) and “Neutral Electrode Safety System” (48) (marketing names for similar functions) built in by some manufacturers or the “Non-contact Capacitive-coupled Patient Return Electrode System” (29,44) are promising solutions for the prevention of pad burns.
- It is better to use bipolar modality and avoid the “coag” mode of monopolar modality in patients who have pacemakers or other electrical implants.
- Activate the electrode only when it is in contact with the tissue or the hemostat grasping the tissue.
- Do not remove the electrode from the tissue while it is active.
- Do not hold your finger underneath the tissue that you cut with electrosurgery. This is also valid for a scalpel cut!
- Work with clean electrodes. Teflon-coated ones are preferable and are quite easy to clean.
- Use gloves of good quality, and glove bites can be generally eliminated by the practice of double gloving.

CONCLUSION

In this study, we tried to highlight the most prevalent complications with demonstrative case illustrations and to elucidate the issues for safer electrosurgery applications. Surgeons should be familiar with the properties and potential complications of electrosurgery, monitoring electrodes and radiofrequency current. The integrity and position of the return electrode should be ensured during surgery. In this time of clinical efficiency-safety and increasing medico-legal consciousness, we think that update courses on electrosurgery should be held regularly as a part of continuing medical education, targeting not only junior level trainees or more senior colleagues, but also non-physician operating room staff.

*Corresponding Address**Dr: Yener DEMİRTAŞ**Ondokuz Mayıs Üniversitesi Tıp Fak. Plast. Rek. Est. Cer. AD.**55139, Kurupelit Samsun, TURKEY**Fax: 362 457 60 41 Phone: 362 312 19 19 / 3608**E-mail: yenerdemirtas@hotmail.com***REFERENCES**

- Cushing H. Electrosurgery as an aid to the removal of intracranial tumors. *Surg Gynecol Obstet.* 1928; 47: 751-784.
- Goldwyn RM. Bovie: the man and the machine. *Ann Plast Surg.* 1979; 2: 135-153.
- O'Connor JL, Bloom DA. William T. Bovie and electrosurgery. *Surgery.* 1996; 119: 390-396.
- Licht S. History of therapeutic heat and cold. In: Lehmann JF (Ed.) *Therapeutic Heat and Cold.* Baltimore, Williams & Wilkins, 1984, Pp: 1-31.
- Ulmer BC. The Valleylab Institute of Clinical Education electrosurgery continuing education module (Valleylab web site). July 2001. Available at: <http://www.valleylabeducation.org>. Accessed August 15, 2004.
- Absten GT. Practical electrosurgery for clinicians (Electrosurgery Professional Medical Education Association, Inc. Associate of the Caribbean Medical Association web site). September 2002. Available at: <http://www.lasertraining.org/electros.htm>. Accessed September 15, 2004.
- Demirtas Y, Menten BB, Tatlicioğlu E. Elektrocerrahi: temel prensipler. *Ankara Cerrahi Derneği,* 2003 (suppl).
- Sudhindra TV, Joseph A, Haray PN, Hacking BC. Are surgeons aware of the dangers of diathermy? *Ann R Coll Surg Eng.* 2000; 82 (suppl): 189-190.
- Mitchell J, Lumb G. The hazards of diathermy in urology. *Proc R Soc Med.* 1960, 53: 348-354.
- Mitchell JP. The isolated circuit diathermy. *Ann R Coll Surg Eng.* 1979; 61: 287-290.
- Miller E, Paull DE, Morrissey K, Cortese A, Nowak E. Scalpel versus electrocautery in modified radical mastectomy. *Am Surg.* 1988; 54: 284-286.
- Shafiqhi M, Huemer GM, Meirer R, Piza-Katzer H. Comparison of epigastric skin flap survival in sharp versus electrocautery dissection in a rat model. *Plast Reconstr Surg.* 2003; 112: 1503-1504.
- Rappaport WD, Hunter GC, Allen R, Lick S, Halldorsson A, Chvapil T, Holcomb M, Chvapil M. Effect of electrocautery on wound healing in midline laparotomy incisions. *Am J Surg.* 1990; 160: 618-620.
- Schemmel M, Warren JS, Haefner HK, Termin CS, Selvaggi SM, Hurd WW. Comparison of the ultrasonic scalpel to CO2 laser and electrosurgery in terms of tissue injury and adhesion formation in a rabbit model. *Fertil Steril.* 1997; 67: 382-386.
- Smith TL, Smith JM. Electrosurgery in otolaryngology-head and neck surgery: principles, advances, and complications. *Laryngoscope.* 2001; 111: 769-780.
- Pollinger HS, Mostafa G, Harold KL, Austin C, Kercher KW, Matthews BD. Comparison of wound-healing characteristic with feed-back circuit electrosurgical generators in a porcine model. *Am Surg.* 2003; 69: 1054-1060.
- Vilos G, Latendresse K, Gan BS. Electrophysical properties of electrosurgery and capacitive induced current. *Am J Surg.* 2001; 182: 222-225.
- Broughton RS, Spencer SK. Electrosurgical fundamentals. *J Am Acad Dermatol.* 1987, 16: 862-867.
- Memon MA. Surgical diathermy. *Br J Hosp Med.* 1994; 52: 403-408.
- Sebben JE. Electrosurgery principles: cutting current and cutaneous surgery-part I. *J Dermatol Surg Oncol.* 1988; 14: 29-31.
- Recommended practices for electrosurgery. *AORN J.* 2004; 79: 432-461.
- Yamagami T, Nakamura T, Kato T, Matsushima S, Iida S, Nishimura T. Skin injury after radiofrequency ablation for hepatic cancer. *AJR.* 2002; 178: 905-907.
- Goette A, Reek S, Klein HU, Geller JC. Case report: severe skin burn at the site of the indifferent electrode after radiofrequency catheter ablation of typical atrial flutter. *J Intervent Card Electrophysiol.* 2001; 5: 337-340.
- Kuzon WM, Crawford R, Binhammer P, Fielding C, Knowlton R, Levine R. Effect of electrosurgical technique on wound healing and early complication rate following abdominal dermolipectomy. *Ann Plast Surg.* 1996; 37: 245-250.
- Molgat YM, Pollack SV, Hurwitz JJ, Bunas SJ, Manning T, McCormack KM, Pinnell SR. Comparative study of wound healing in porcine skin with CO2 laser and other surgical modalities: preliminary findings. *Int J Dermatol.* 1995; 34: 42-47.
- Middleton WG, Tees DA, Ostrowski M. Comparative gross and histological effects of the CO2 laser, Nd-YAG laser, scalpel, shaw scalpel, and cutting cautery on skin in rats. *J Otolaryngol.* 1993; 22: 167-170.
- Pillinger SH, Delbridge L, Lewis DR. Randomized clinical trial of suction versus standard clearance of the diathermy plume. *Br J Surg.* 2003; 90: 1068-1071.
- Aigner N, Fialka C, Fritz A, Wruhs O, Zoch G. Complications in the use of diathermy. *Burns.* 1997; 23: 256-264.
- Sheridan RL, Wilson NC, O'Connell MF, Fabri JA. Noncontact electrosurgical grounding is useful in burn surgery. *J Burn Care Rehabil.* 2003; 24: 400-401.
- Golombek MA, Dossel O, Raiser J. Improvement of patient return electrodes in electrosurgery by experimental investigations and numerical field calculations. *Med Biol Eng Comput.* 2003; 41: 519-528.
- Nicholson M. A third-degree burn secondary to faulty electrocautery ground. *Anesth Analg.* 1970; 49: 402-405.
- Parikh S, Mehlman CT, Keith RW. A third-degree burn caused by a neurogenic motor-evoked potential monitoring electrode during spinal surgery: a case report. *Spine.* 2003; 28: E1-E24.
- Brennand R. Electrical hazards of disposable monitoring electrodes. *Lancet.* 1975; 1: 1240-1241.

34. Orpin JA. Unexpected burns under skin electrodes. *Can Med Assoc J.* 1982; 127: 1106.
35. Becker CM, Malhotra IV, Hedley-Whyte J. The distribution of radiofrequency current and burns. *Anesthesiology.* 1973; 38: 106-122.
36. LoCicero J III, Fisher E, Atlas PL, Shanks C, Wade RJ, Michaelis LL. Remote skin injury: a protean complication of open heart surgery. *Am Surg.* 1986; 52: 97-100.
37. Rajek A, Lenhardt R, Sessler DI, Grabenwoger M, Kastner J, Mares P, Jantsch U, Gruber E. Tissue heat content and distribution during and after cardiopulmonary bypass at 31°C and 27°C. *Anesthesiology.* 1998; 88: 1511-1518.
38. Sullivan B, Kenney P, Seibel M. Hysteroscopic resection of fibroid with thermal injury to sigmoid. *Obstet Gynecol.* 1992; 80: 546-547.
39. Jinhua L, Jinghe L, Rongli H, Zhufeng L, Dawei S. Complications in laparoscopic gynecologic surgery. *Chi Med Sci J.* 2000; 15: 222-226.
40. Freilich TH. Possibility of burns during laparoscopic tubal sterilization. *Am J Obstet Gynecol.* 1977; 129: 708.
41. Lo KWK, Yuen PM. Mortality following laparoscopic surgery. *Gynecol Obstet Invest.* 1999; 48: 203-204.
42. Soderstrom RM. Bowel injury litigation after laparoscopy. *J Am Assoc Gynecol Laparosc.* 1993; 1: 74-77.
43. Nduka CC, Super PA, Monson JRT, Darzi AW. Cause and prevention of electrosurgical injuries in laparoscopy. *J Am Col Surg.* 1994; 179: 161-170.
44. Man D. Reducing the hazards of burns from bovie pads. *Plast Reconstr Surg.* 2000; 106: 947.
45. Goldberg SN, Solbiati L, Halpern EF, Gazelle GS. Variables affecting proper system grounding for radiofrequency ablation in an animal model. *JVIR.* 2000; 11: 1069-1075.
46. Edrich J, Cookson CC. Electrosurgical dispersive electrodes heat cutaneous and subcutaneous skin layers. *Med Instrum.* 1987; 21: 81-6.
47. Neutral Electrode Monitoring. (Aaron medical web site). Available at: <http://www.aaronmed.com/ProdGen1250.html>. Accessed June 15, 2004.
48. NESSY, the Neutral Electrode Safety System. (ERBE Elektromedizin GmbH web site). Available at: http://www.erbe-med.com/hf_e/nessy.html. Accessed June 15, 2004.
49. Duxbury MS, Blake SM, Dashfield A, Lambert AW. A randomised trial of knife versus diathermy in pilonidal disease. *Ann R Coll Surg Eng.* 2003; 85: 405-407.
50. Keenan KM, Rodeheaver GT, Kenney JG, Edlich RF. Surgical cautery revisited. *Am J Surg.* 1983; 147: 818-821.
51. Demirtas Y, Yavuzer R. Bloodless pedicle deepithelialization in reduction mammoplasty. *Plast Reconstr Surg.* 2003; 112: 1742-1743.
52. Lee TW, Chen TM, Cheng TY, Chen SG, Chen SL, Chou TD, Chou GH, Lee CH, Wang HJ. Skin injury in the operating room. *Injury.* 1998; 29: 345-347.
53. Parker EO III. Electrosurgical burn at the site of an esophageal temperature probe. *Anesthesiology.* 1984; 61: 93-95.
54. Bloch EC, Burton LW. Electrosurgical burn while using a battery-operated Doppler monitor. *Anesth Analg.* 1979; 58: 339-342.
55. Ruggera PS, Witters DM, von Maltzan G, Bassen HI. In vitro assessment of tissue heating near metallic medical implants by exposure to pulsed radio frequency diathermy. *Phys Med Biol.* 2003; 48: 2919-2928.
56. Dagradi AE, Severance SR, Duckor SL, Van Herrick R. Complication during endoscopic electrosurgical polypectomy at the gastric cardia. *Am J Gastroenterol.* 1977; 67: 593-599.
57. Inan A, Dener C, Demirci S. Explosion during diathermy gastrotomy in a patient with carcinoma of the antrum. *Int J Clin Pract.* 2003; 57: 737-738.