

SUPERIOR GLUTEAL ARTERY PERFORATOR FLAP: AN ALTERNATIVE IN THE TREATMENT OF COMPLICATED PILONIDAL SINUS*

Selahattin ÖZMEN, Sebahattin KANDAL, Fulya FINDIKÇIOĞLU, Bülent MENTEŞ*

Purpose: Although the majority of sacrococcygeal pilonidal sinuses can be treated with simple surgical procedures, some persistent cases are encountered.

Materials and Methods: This article describes an 18-year-old male who presented with chronic pilonidal sinus disease, which was resistant to different treatment modalities applied over the previous four years. He was treated with a superior gluteal artery pedicled perforator flap from the left hip after complete excision of all the sinuses.

Results: No complication was observed during the postoperative period. The patient was healthy and no recurrence was observed during the 12-month follow-up period.

Conclusion: The superior gluteal artery perforator flap is not the first choice for treating sacrococcygeal pilonidal sinuses; however, it provides a reliable pathophysiological solution for the surgical reconstruction of recurrent, obstinate, wide and especially long pilonidal sinus cases.

Key Words: Superior gluteal artery, perforator, flap, SGAP, pilonidal sinus

SUPERIOR GLUTEAL ARTER PERFORATOR FLEBİ: KOMPLİKKE PİLONİDAL SİNÜS TEDAVİSİNDE BİR ALTERNATİF

Giriş: Sakrokoksigeal pilonidal sinüslerin birçoğu basit cerrahi tekniklerle tedavi edilebilmesine rağmen bazı olgular tedaviye oldukça dirençlidirler.

Olgu Sunumu: Bu çalışmada, son 4 yılda çeşitli tedavilere rağmen iyileşmeyen pilonidal sinus şikayetiyle başvuran 18 yaşında bir erkek hastayı sunduk. Tüm sinüslerin geniş bir şekilde eksizyonunu takiben hastanın sol tarafından hazırlanan superior gluteal arter pediküllü perforatör flebi ile defekt onarıldı.

Bulgular: Postoperatif dönemde komplikasyon olmadı. Hastanın 12 aylık takiplerinde bir sorun saptanmadı.

Sonuç: Süperior gluteal arter perforatör flebi sakrokoksigeal pilonidal sinüslerin tedavisi için ilk tercih değildir. Ancak, tekrarlayan, dirençli, geniş ve özellikle vertikal boyu uzun olguların tedavisi için uygun patofizyolojik bir çözüm sağlayabilir.

Anahtar Kelimeler: Süperior gluteal arter, perforatör, flep, SGAP, pilonidal sinus

INTRODUCTION

Several therapy modalities have been introduced for the treatment of pilonidal sinus (1). Although the majority of patients can be treated with simple surgical procedures, sometimes chronic recurrent/persistent sacral pilonidal disease has a negative impact on the patient's lifestyle.

Here we present a patient with chronic sacral pilonidal sinus successfully treated with superior gluteal artery perforator flap. The technique and the outcome are discussed.

CASE REPORT

An 18-year-old male presented with chronic pilonidal sinus disease, which was resistant to different treatment modalities applied over the previous four years, including drainage, fistulotomy and curettage. In the physical examination, there were multiple sinus openings from just above the anus up to the upper intergluteal sulcus. There was minimal serous discharge with pressure on the tracts but no abscess formation was detected (Fig. 1).

A deep, wide intergluteal defect was estimated after the complete excision of the sinus, therefore a left hip superior gluteal artery pedicled perforator flap was planned.

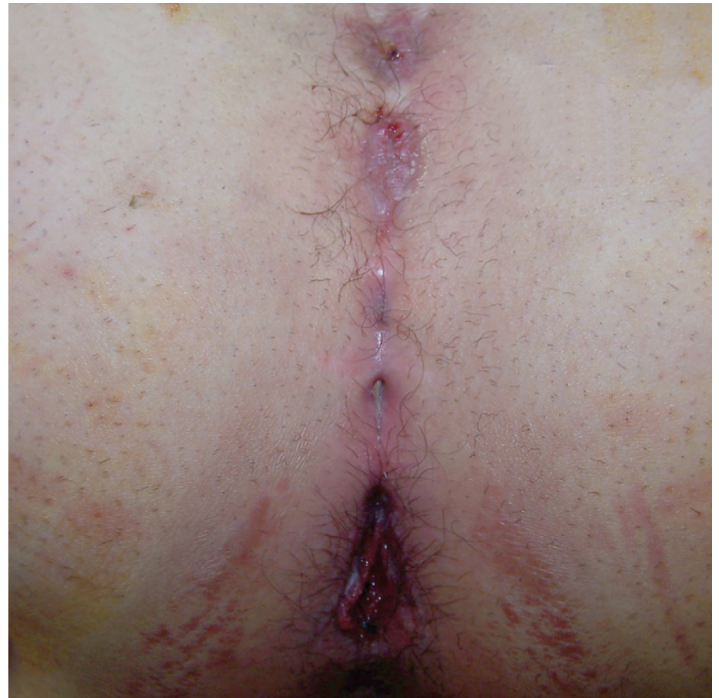

Figure 1: Preoperative view of the long pilonidal sinus, extending from just above the anus to the upper intergluteal sulcus.

* Presented at the 74th ASPS, PSEF, ASMS Scientific Meeting (Chicago, IL, USA, September 24–28, 2005).

Gazi Üniversitesi Tıp Fakültesi

Plastik, Rekonstrüktif ve Estetik Cerrahi A.D. ve Genel Cerrahi* A.D.

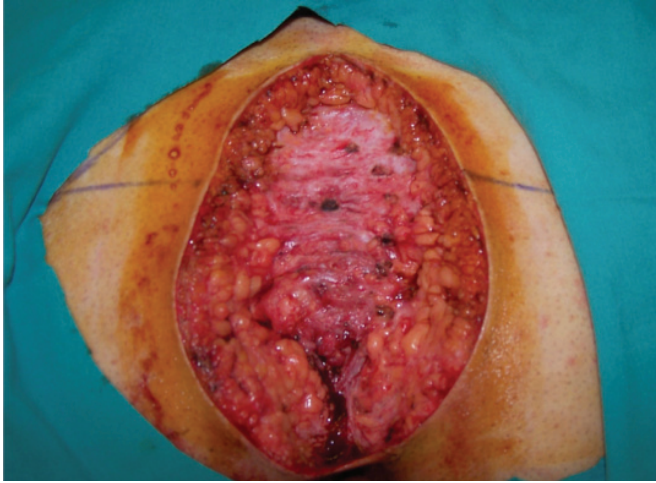


Figure 2: Vertical elliptical excision of the pilonidal sinus down to the postsacral fascia, leaving a wide defect.

Anatomy and operative technique

The superior gluteal artery (SGA), which is the terminal branch of the internal iliac artery, emerges from the suprapiriform foramen. After giving a deep branch to the gluteus medius muscle, it runs through the gluteus maximus (2). End cutaneous branches of this artery perforate the fascia of the gluteus maximus and supply blood to the superolateral gluteal region. Based on one of these cutaneous perforator arteries it is possible to raise skin flaps as wide as 30 cm X 13 cm with a pedicle length of 6 to 10.5 cm, leaving the muscle intact both anatomically and functionally (3,4).

A handheld acoustic Doppler ultrasound device can be used to locate these perforators and the SGA along its latero-distal direction as described by Verpael et al. (3).

The direction of the flap should be from mediocranial to laterocaudal, horizontal or slightly oblique. This design allows for a completely well-adjusted skin tension and hidden scar beneath underwear, as well as converting the flap intraoperatively into a rotation flap in case of a lack of a suitable perforator vessel.

In order to obtain a flap with a wide arc of rotation on the perforator, the most lateral perforator was targeted, located with handheld Doppler USG and marked preoperatively. After urinary catheterization, under spinal anesthesia a vertical elliptical excision of the pilonidal sinus was carried down to the post-sacral fascia leaving approximately a 15 X 10 cm defect behind (Fig. 2). The flap was designed according to the defect size and shape. Initially the superior border of the flap was incised down to the fascia of the muscle without beveling. Flap harvesting started from the superolateral part above the fascia parallel to the direction of the gluteus maximus fibers. After coming across to the determined perforator, the fascia was incised and the dissection of the perforator continued within the muscle up to its anterior surface by carefully clipping its small muscular side branches using loop magnification. Near the anterior surface to the muscle small motor branches were observed and preserved. Once the perforator vessel was dis-

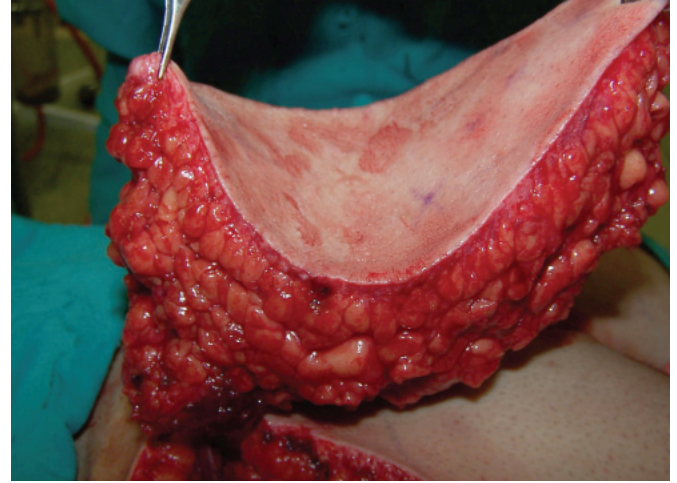


Figure 3: The flap was elevated completely, holding only from its perforator.

sected far enough, the inferior margin of the flap was incised and the flap was elevated completely from the fascia on the single perforator, leaving the gluteal muscle intact (Fig. 3). The horizontally designed fasciocutaneous perforator flap was transposed to the defect in a vertical orientation by cutting of the skin bridge between the defect and the donor site. It is important to remember that the perforator should be embedded in a safety soft tissue cover, like muscle, and should be kept untwisted. Two suction drains were applied under the flap and to the donor area. The donor site was closed primarily and the flap was secured to the defect in two layers.

No complication was observed in the postoperative period. The suction drains were removed and mobilization was permitted gradually on the second postoperative day. The patient was permitted to move freely after two weeks.

The patient was doing well without any complication at the 12th postoperative month (Fig. 4).

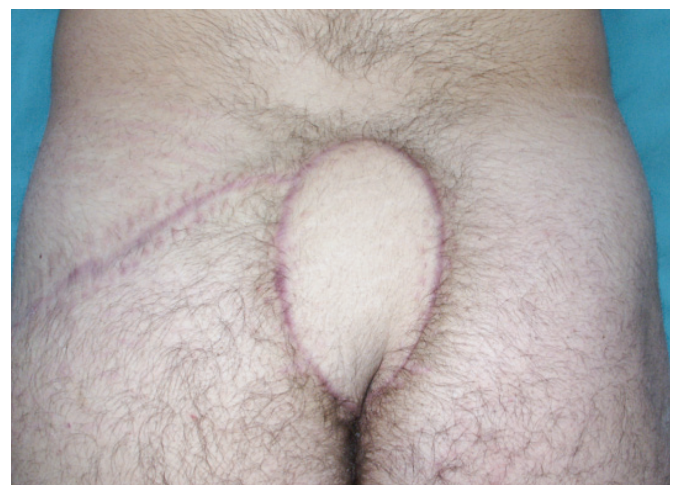

Figure 4: Postoperative view of the patient 12 months later with no evidence of recurrence. The scar remains hidden under normal underwear.

The ideal operation for pilonidal sinus treatment should be simple, require short hospitalization, have a low recurrence rate and be cost effective. Various surgical procedures have been described for the treatment of pilonidal sinuses (1,5-6). Excision and primary closure, cryosurgery, sclerosing injection, and skin grafting are the simple ones. Flap alternatives are transposition flap procedures such as Z-plasty, W-plasty, rhomboid, Dufourmental, Limberg, modified Limberg, V-Y advancement flaps, gluteus maximus myocutaneous flaps and rotational cutaneous flaps. The majority of the patients can be healed with these procedures. However, there is a small group that is resistant to treatment with recurrent sinuses and chronic wounds. These patients may need multiple and extensive reconstructive procedures. However, extensive flap surgery, especially when a muscle is involved in the flap, is not suitable for young and ambulatory patients. In this case a cutaneous or fasciocutaneous flap that can move extensively and does not compromise muscular function is needed.

Perforator flaps offer a new perspective in microsurgical tissue transfers; therefore they have become increasingly popular among plastic surgeons in recent years. A perforator is an arterial branch that has its origin in one of the axial arteries of the body together with its venous vessel and passes through certain structural elements of the body to ultimately pierce the deep fascia and constructs the subcutaneous vascular plexus. A perforator flap consists of skin and/or a subcutaneous fat layer. While harvesting a perforator skin flap, preservation of the muscle innervation, vascularizations as well as the completeness of the underlying structures with less postoperative pain and functional restoration are the major advantages. These flaps are free to move in almost every direction; they can be designed in very large dimensions and in the desired shape.

A superior gluteal artery perforator (SGAP) flap was used as a free flap in autologous breast reconstruction, and as a pediculated flap in the reconstruction of dorsal lower trunk area defects and large sacral and gluteal pressure sores (7). From another perspective, the SGAP flap is an updated version of traditional hip musculocutaneous flaps. The superiority of the pediculated SGAP flap over the classical advanced gluteus maximus musculocutaneous flaps stems from its highly increased mobility and the three-dimensional harmony even in the midline of the sacral defects as well as muscle integrity and intact muscle function.

A SGAP flap not only fills up the intergluteal defect but

also flattens the cleft in a perfect manner without sheltering any scar or stitch holes in the midline of the cleft, which is a risk for recurrence.

The drawbacks of this procedure are the extended surgical time, steep learning curve, and need for microsurgical instruments and loop magnification.

CONCLUSION

The superior gluteal artery perforator flap is not the first choice for all sacrococcygeal pilonidal sinuses. However, it provides a reliable pathophysiological solution for the surgical reconstruction of recurrent, obstinate, wide pilonidal sinuses of the sacrococcygeal region. Therefore, one should remember that in complicated, especially long pilonidal sinuses, a SGAP flap might be a good solution in young patients, leaving muscular function intact.

Corresponding Address

Selahattin ÖZMEN, MD

58 Sk. 18/2 Emek, Cankaya, 06510 Ankara/TURKEY

Phone: 90-312-215 8208 Fax: 90-312-212 9908

E-mail:selozmen@gazi.edu.tr

REFERENCES

1. Cihan A, Montes BB, Tatlicioglu E, Ozmen S, Leventoglu S, Ucan BH. Modified Limberg flap reconstruction compares favourably with primary repair for pilonidal sinus surgery. ANZ J Surg. 2004; 74: 238-42.
2. Koshima I, Moriguchi T, Soeda S, Kawata S, Ohta S, Ikeda A. The gluteal perforator-based flap for repair of sacral pressure sores. Plast Reconstr Surg. 1993; 91: 678-83.
3. Verpaele AM, Blondeel PN, Van Landuyt K, Tonnard PL, Decordier B, Monstrey SJ, Matton G. The superior gluteal artery perforator flap: an additional tool in the treatment of sacral pressure sores. Br J Plast Surg. 1999; 52: 385-91.
4. Blondeel PN, Demuyneck M, Mete D, Monstrey SJ, Van Landuyt K, Matton G, Vanderstraeten GG. Sensory nerve repair in perforator flaps for autologous breast reconstruction: sensational or senseless? Br J Plast Surg. 1999; 52: 37-44.
5. Hull TL, Wu J. Pilonidal disease. Surg Clin North Am. 2002; 82: 1169-85.
6. Nessar G, Kayaalp C, Seven C. Elliptical rotation flap for pilonidal sinus. Am J Surg. 2004; 187: 300-3.
7. Blondeel PN, Van Landuyt K, Hamdi M, Monstrey SJ. Soft tissue reconstruction with the superior gluteal artery perforator flap. Clin Plast Surg. 2003; 30: 371-82.