

## CASE REPORTS

# BEE STING OF THE CORNEA: A CASE REPORT

## KORNEYA ARI SOKMASI: OLGU SUNUMU

Sevin Soker ÇAKMAK, M.D.,  
Seyhmus ARI, M.D.

İhsan CACA, M.D.,

M. Kaan UNLU, M.D.,

Dicle University Faculty of Medicine, Department of Ophthalmology, Diyarbakır, Turkey.  
Gazi Medical Journal 2004; 15: 145-147

**SUMMARY:** We present a case of corneal bee sting with retained stinger apparatus. The patient suffered from pain, blurred vision, and epiphora. Visual acuity of the left eye was 1/10. The affected eye showed conjunctival hyperemia, keratitis, and infiltration of the paracentral cornea by microscopic examination. The stinger was identified within the cornea infiltration and was removed surgically. Bee sting of the cornea, while very rare, has the potential to cause serious ophthalmologic injury.

**Key Words:** Cornea, Corneal Edema, Bee Sting.

**ÖZET:** Korneayı arı sokması ile korneada arının iğnesinin kaldığı bir olguyu sunduk. Hastanın sol gözünde bulanık görme, ağrı ve sulanma şikayetleri mevcuttu. Hastanın sol gözünde görme keskinliği 1/10'du. Sol göz biomikroskopik muayenesinde, konjonktival kızarıklık ve kornea parasantralinde keratit ve infiltrasyon mevcuttu. Korneal infiltrasyonun içerisinde arının iğnesi mevcuttu. İğne cerrahi olarak çıkartıldı. Korneayı arı sokması çok nadir görülmekle birlikte ciddi oftalmik yaralanmaya neden olma potansiyeline sahiptir.

**Anahtar Kelimeler:** Kornea, Korneal Ödem, Arı Sokması.

## INTRODUCTION

Bee stings of the eye are uncommon. Quite a few clinical case reports have documented various ocular reactions to bee venom, which may range from mild conjunctivitis to sudden loss of vision. Reactions to the venom may be toxic or immunological. Generally, it is thought that reactions associated with a retained stinger are more often the result of injected toxins rather than due to the presence of the stinger itself (1). Animal research and human experience have shown that once the venom is inactivated, the stinger is completely inert (2,3).

We present a case of a corneal bee sting with retained stinger apparatus, together with the evaluation and treatment of this uncommon presentation.

## CASE REPORT

A 21-year-old man presented with pain, blurred vision and epiphora 1 week following a bee sting to the left eye. Visual acuity was 0.1. An examination revealed the pupils to be equal, round, and reactive to light, with marked photophobia. The extraocular muscles were intact, and conjunctival injection was noted. Instillation into the left eye of two drops of the cycloplegic cyclopentolate afforded relief and facilitated a normal fundusoscopic examination. The eye showed conjunctival hyperemia, striate keratitis, and infiltration of the paracentral cornea at the 12 o'clock meridian; +2 cells and flare were evident in the anterior chamber by slit lamp examination. Two drops of tropicamide, a topical ophthalmic anesthetic, and fluorescein stain were placed in the left eye, and the stinger was

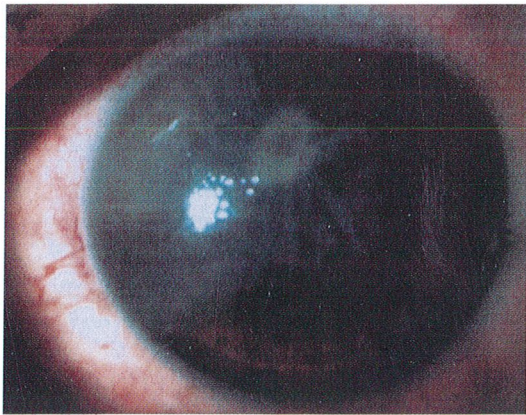


Fig. 1A: Edema and infiltration in the paracentral cornea after surgery.

identified within the cornea infiltration. It was removed surgically (Fig. 1a, Fig. 1b). The patient was discharged with 0.3% tobramycin 4x1, 0.1% dexamethasone 4x1, 1% cyclopentolate HCl 4x1, lodoxamide tromethamine 4x1. After 3 months the eye showed opacification of the cornea with fine neovascularizations. Visual acuity was 6-10.

#### DISCUSSION

Bee stings of the cornea are very rare, and responses can range from minimal to severe. Clinical reactions to bee stings of the cornea are caused by the toxic or immunological effects of different components of bee venom. Toxicity and inflammation can lead to serious intraocular damage, such as lens dislocation, cataract formation, iris atrophy, ophthalmoplegia, or neuropathy (4).

Bee venom is a complex toxin composed of several compounds with different actions (5,6). Toxicity is primarily related to the presence of two groups of biological amines: nonenzymatic polypeptide toxins (melittin, apamin, iminimine, mast-cell degranulating peptide) and enzymes (phospholipase A, phospholipase B, hyaluronidase) (7). The immediate, severe toxic effects of a sting are precipitated primarily by the biogenic amines melittin and apamin (2,8). By virtue of their high molecular weights, the enzymes are also highly antigenic, and account for the immunological injury to the eye following cornea stings. This occurs via a type I hypersensitivity reaction mediated by IgE, with

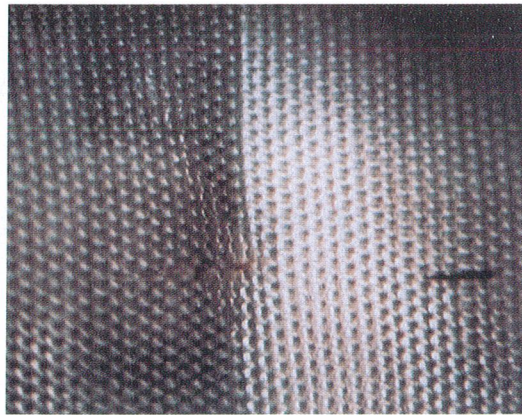


Fig. 1B: The stinger removed during surgery.

release of chemical mediators of inflammation, and is manifested by conjunctival injection, chemosis, and cornea edema (2,7).

Cornea bee stings have been associated with a significant ocular pathology. Chen et al. (8) reported the development of severe conjunctival injection, chemosis, marked cornea edema, and hyphema in a 6-year-old boy stung on the right cornea. A partially dislocated lens, partial iris atrophy, and cataract formation were subsequently noted. The child was treated with systemic and topical corticosteroids. Choi et al. (9) reported the case of a 46-year-old man who presented with sudden visual loss after being stung by a bee on the left conjunctiva. He developed optic disc swelling and a delayed p100 wave in pattern visual evoked potentials.

This case suggests that early corticosteroid treatment is effective. No development of cataract, dislocated lens, iris atrophy, or optic neuritis were observed. Three months after treatment, only opacification of the cornea with mild corneal neovascularization had developed. In the present case, the patient came to us a week after the bee sting. The development of opacification, despite the surgical and medical procedures employed, indicates the importance of immediate treatment of bee sting patients.

Beekeeping is important in our region, where agriculture and livestock husbandry are a major means of subsistence. Bee stings will continue to be an important hazard and, while stings of the

cornea are rarely reported, they have the potential to cause serious ophthalmologic injuries. Physicians must take into consideration the potential triad of penetrating, toxic, and immunological injuries. The current treatment of choice is systemic and local application of steroids and antibiotics, as well as local therapy with antihistamines.

Correspondence to: Sevin Soker ÇAKMAK, M.D.  
Dicle Üniversitesi Tıp Fakültesi  
Göz Hastalıkları Anabilim Dalı  
21280 DİYARBAKIR, TÜRKİYE  
Phone: 412 - 233 98 50  
Fax: 412 - 248 84 40  
E-mail: sokers@dicle.edu.tr

#### REFERENCES

1. Tuft SJ, Crompton DO, Coster DJ. Insect sting in a cornea. *Am J Ophthalmol* 1985; 99: 727-728.
2. Smolin G, Wong I. Bee sting of the cornea: case report. *Ann Ophthalmol* 1982; 14: 342-343.
3. Gilboa M, Gdal-On M, Zonis S. Bee and wasp stings of the eye. Retained intralenticular wasp sting: A case report. *Br J Ophthalmol* 1977; 61: 662-664.
4. Grub M, Mielke J, Schlote T. Bee sting of the cornea - a case report. *Klin Monatsbl Augenheilkd* 2001; 218: 747-750.
5. Smith DG, Roberge RJ. Corneal bee sting with retained stinger. *J Emerg Med* 2001; 20: 125-128.
6. Mackler BF, Kreil G. Honey bee venom melittin: correlation of nonspecific inflammatory activities with amino acid sequences. *Inflammation* 1977; 2: 55-65.
7. Yildirim N, Erol N, Basmak H. Bee sting of the cornea: a case report. *Cornea* 1998; 17: 333-334.
8. Chen CJ, Richardson CD. Bee sting-induced ocular changes. *Ann Ophthalmol* 1986; 18: 285-286.
9. Choi MY, Cho SH. Optic neuritis after bee sting. *Korean J Ophthalmol* 2000; 14: 49-52.