

RESEARCH ARTICLES

SKIN LESIONS IN HEROIN-FLUNITRAZEPAM ADDICTS: AN UNUSUAL TYPE OF MIXED DRUG ABUSE BETWEEN 1997 AND 2002

EROİN-FLUNİTRAZEPAM BAĞIMLILARINDA CİLT LEZYONLARI: 1997-2002 YILLARI ARASINDA ALIŞILMADIK KARIŞIK MADDE KÖTÜYE KULLANIMI

Gürol CANTÜRK MD,

A.Sedat ÇÖLOĞLU MD*,

Yalçın ERGEZER MD**

Ankara University School of Medicine, Forensic Medicine Department, Ankara, Turkey
Yeditepe University School of Medicine*, İstanbul, Turkey
State Institute of Forensic Medicine**, İstanbul, Turkey

Gazi Medical Journal 2004; 15: 83-86

ABSTRACT

Purpose: To describe and present for the first time the typical skin lesions at the injection sites of drug addicts using an unusual combination of heroin and flunitrazepam. **Methods:** Regarding drug dependence, 1869 patients were assessed over a 6-year period during 1997-2002, at the State Institute of Forensic Medicine, 4th Specialization Department. **Results:** This study is composed of 7 unique cases of typical skin lesions in which forensic medical observations were established at the State Institute of Forensic Medicine, Department of Forensic Psychiatry, İstanbul, Turkey, from January 1997 to January 2003. Seven male heroin-flunitrazepam users (age range, 36-53 years; average, 41 years) were identified among the 38 heroin addicts. The patients were living in the same district in İstanbul and knew each other; they were members of the so-called heroin/flunitrazepam clone. According to their explanation, this was the best and cheapest way to enhance the high feeling when they could buy only a small amount of heroin. **Conclusion:** We described unusual skin lesions of mixed drug addicts. This is the first report describing the clinical findings of heroin/flunitrazepam lesions at the injection sites.

Key Words: Heroin/Flunitrazepam Combination, Skin lesions, Heroin Addicts.

INTRODUCTION

Oral, sublingual and intravenous (IV) methods are used in drug abuse. IV drug abuse has many known complications. The most common are thrombosis and thrombophlebitis, cellulitis, embolism, subacute bacterial endocarditis, hepatitis and AIDS. Less commonly, rhabdomyolysis and aneurysm have been described (1).

ÖZET

Amaç: Bu çalışmanın amacı, daha önce bildirilmemiş alışılmadık şekilde eroin ve flunitrazepam kombinasyonu kullanan madde bağımlılarının enjeksiyon bölgelerindeki tipik cilt lezyonlarını tanımlamak ve sunmaktır. **Metod:** İstanbul Adli Tıp Kurumu 4. İhtisas Kurulunda 1997-2002 yılları arasında kapsayan 6 yıllık sürede madde bağımlılığı yönünden muayene edilen 1869 olgu değerlendirilmiştir. **Bulgular:** Ocak 1997'den Ocak 2003'e kadar olan dönemde, Adli Psikiyatri bölümünde muayene edilen olgulardan 7'sinde tipik cilt lezyonları tespit edilmiştir. Yaşları 36-53 arasında değişen 7 erkek eroin-flunitrazepam kullanan olgu eroin bağımlısı olarak değerlendirilen 38 olgunun içinde idi. Bu hastalar İstanbul'un aynı bölgesinde yaşıyor ve birbirlerini tanıyorlardı. Eroin-flunitrazepam klonunun bir üyesi gibiydiler. Onların açıklamasına göre sadece az miktarda eroin ile kendilerini daha iyi hissetmelerinin en ucuz ve en iyi yoluydu. **Sonuç:** Literatür bilgilerimize göre enjeksiyon bölgelerindeki eroin/flunitrazepam kullanımına bağlı alışılmadık cilt lezyonları ilk kez tanımlanmıştır.

Anahtar Kelimeler: Eroin/Flunitrazepam Kombinasyonu, Cilt Lezyonları, Eroin Bağımlısı.

In this study, 38 out of 367 heroine users were diagnosed as drug dependent (10.35%). Seven of those diagnosed as heroin dependent reported that they were using heroin combined with flunitrazepam tablets by IV injection. In the cases reported below, unusual skin lesions of IV heroin-flunitrazepam combination injection sites among 38 heroin addicts are described, which, to the best of our knowledge, have not been

previously reported.

MATERIAL AND METHODS

Over a 6-year period (1997-2002), 1869 patients were assessed with regard to drug dependence at the 4th Specialization Department, State Institute of Forensic Medicine. The patients were evaluated based on age, sex and kind of substance used. Their medical and legal files (court files obtained for determining drug dependence) were also examined. The determination of drug dependence was based on the DSM- IV criteria. Toxicologic analyses were performed by immunoassay (CEDIA) and GC/MS methods.

This study is composed of 7 unique cases of typical skin lesions identified among 367 narcotic users in which forensic medical observations were performed at the Department of Forensic Psychiatry, the Institute of Forensic Medicine of Turkey, Istanbul, Turkey, from January 1997 to January 2003.

RESULTS

Over the 6-year period (1997-2002), 1869 patients were assessed with regard to drug dependence at the 4th Specialization Department. They were examined based on their medical files and the decision concerning drug dependence was based on the DSM-IV criteria.

Marijuana was used by 1459 of the entire 1869 patients (78.06%), heroin by 367 (19.63%), marijuana and heroin by 35 (1.87%), and cocaine by 8 (0.42%). In the assessment of the patients, who were almost merely male (only 11 female), according to the DSM-IV criteria 38 of the 367

heroin users were diagnosed as drug dependent (10.35%). No drug dependence diagnoses were made for any of the users of other kinds of substance. Seven of those diagnosed as heroin dependent reported that they were using heroin combined with flunitrazepam tablets by IV injection. No other psychiatric pathology was observed in the above-mentioned cases.

Seven male heroin-flunitrazepam addicts (age range, 36-53 years; average, 41 years) were identified among the 367 (heroin) narcotic users. The patients were living in the same district in Istanbul, and knew each other; they were members of the so-called heroin/flunitrazepam-clone.

According to their explanation, they began to inject flunitrazepam after they had become addicted to heroin, and this was the best and cheapest way to enhance the high feeling when they could only buy an amount of heroin that was lower than their daily intake.

Clinical examinations of the patients revealed healed ulcers with clearcut and definite margins, and the bases of the lesions were generally smooth and dry, with some loss of cutaneous pigmentation or hyperpigmentation. These skin lesions were defined only macroscopically.

In general, isolated lesions measured 0.5-2.0 cm in diameter, and 0.2-0.3 cm in depth. In some of the addicts, there were lesions showing conglomerations. In all of the patients, the lesions were mostly found on the arms and legs. Additionally, hip and neck lesions were observed

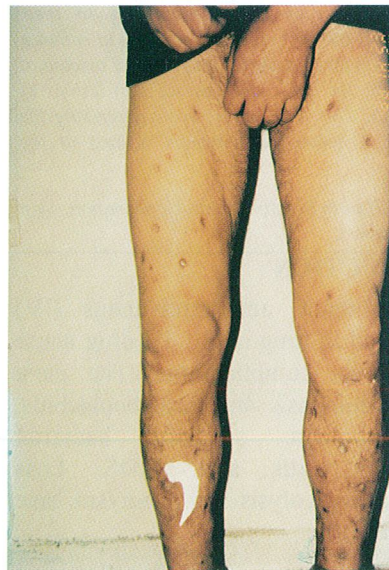
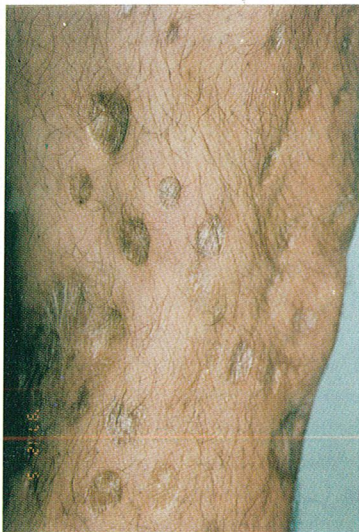
Fig. 1AB: Typical skin lesions of the addicts.

in two patients (Fig. 1AB).

Toxicologic studies of the blood performed in all of the patients revealed morphine, codeine and flunitrazepam (Fig. 2, 3).

DISCUSSION

Drug abuse frequently progresses in stages, from occasional use, to regular use, to multiple drug use, and ultimately to total dependency. With each successive stage, drug use intensifies, becomes more varied, and results in increasingly debilitating effects.

Benzodiazepines are the favorite co-drugs of multiple and mixed drug addicts in some countries. The use of heroin together with benzodiazepines is beginning to show disturbing increases in surveys performed in Israel (2),

Spain (3), Malaysia (4), Wales (5) and France (6).

Flunitrazepam is the most commonly abused benzodiazepine in some regions (2-5,7,8). In some countries, most addicts prefer swallowing benzodiazepines to IV injection (5). On the other hand, flunitrazepam may have greater liability for abuse than others; such suggestions are supported by surveys of opioid abusers (9).

In Turkey, benzodiazepine abuse could become a considerable problem in heroin addicts both entering and during methadone maintenance. Consumption of flunitrazepam by the patients in this paper began after they had become addicted to heroin. Skin lesions of drug addicts may attract the physician's attention to the composition of injected chemical(s), especially those seen in heroin/flunitrazepam users. The local skin reaction in a heroin addict may be defined as an acute inflammatory episode, chemical in origin, which is superimposed on the normal course of the infections caused by contaminated material. The findings show that reactions in the skin are predominantly a response to heroin. Additional chemical(s) may cause severe reactions with necrosis. In our patients, necrosis was seen only in the members of the heroin/flunitrazepam clone among the 367 narcotic (heroin) users. In these subjects, if the flunitrazepam load is high, profuse edema may be associated with liquefaction necrosis developing deep in the injection site. With a low flunitrazepam load, small foci of necrosis are more likely to involve the superficial parts of the skin. The appearance of typical heroin/flunitrazepam lesions at the time of clinical examination will depend on the stage of development. They may be active, erythematous and succulent or may consist of a wide, depressed, dry and scaly ring with a punched-out appearance. Superficial lesions heal more rapidly in a healthy addict.

In summary, we have described unusual skin lesions in mixed drug addicts, and to our knowledge this is the first report describing the clinical findings of heroin/flunitrazepam lesions at the injection sites.

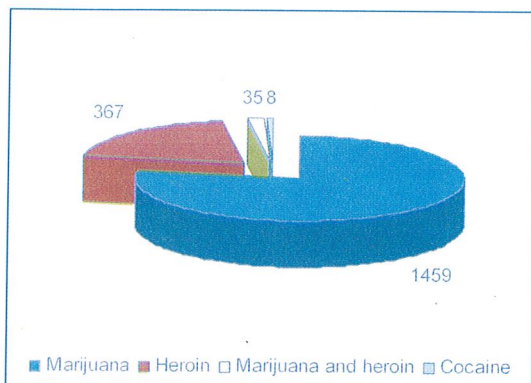


Fig. 2: Drug Users.

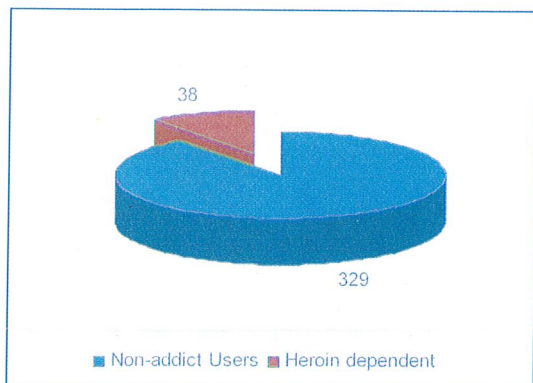


Fig. 3: Heroin Users.

Correspondence to: Gürol CANTÜRK , M.D.
Ankara Üniversitesi Adli Tıp
Anabilim Dalı
Cebece
ANKARA - TÜRKİYE
Phone: 312 319 1514
E-mail: canturk@medicine.ankara.edu.tr

REFERENCES

- 1- Cologlu AS. 1997. Autopsy findings in drug addicts, Handbook for Forensic Pathologists, Department of Forensic Medicine, Cerrahpasa School of Medicine, Istanbul University.
- 2- Gelkopf M, Bleich A, Hayward R, Bodner G, Adelson M. Characteristics of benzodiazepine abuse in methadone maintenance treatment patients: a 1 year prospective study in an Israeli clinic. *Drug Alcohol Depend*, 1999; 55: 63-68.
- 3- San Marco JL, Jouglard J, Thirion X, Albertini F, Arditi J, Coulouvrat H, Delaroziere JC, Glezer D, Monie, S, Prat P, Santucci JJ, Spadari M, Tanche B, Lagier G. Observation des produits psychotropes illicites ou detournes de leur utilisation medicamentause (O.P.P.I.D.U.M.): cinq ans de surveillance des produits consommés par les toxicomanes a Marseille, *Therapie*, 1996; 51: 586-598.
- 4- Navaratnam V, Foong K. Opiate dependence—the role of benzodiazepines. *Curr Med Res Opin*, 1990; 11: 620-630.
- 5- Darke SG, Ross JE, Hall WD. Benzodiazepine use among injecting heroin users. *Med J Aust*, 1995; 162: 645-647.
- 6- Salvaggio J, Jacob C, Schmitt C, Orizet C, Ruel M, Lambert H. Consommation abusive de flunitrazepam par les toxicomanes aux opiaces. *Annales de Medecine Interne*, 2000; 151 (Suppl.) A: A6-9.
- 7- San L, Tato J, Torrens M, Castillo C, Farre M, Cami J. Flunitrazepam consumption among heroin addicts admitted for in-patient detoxification. *Drug Alcohol Depend*, 1993; 32: 281-286.
- 8- Barattini M, Fantozzi R, Masini E, Mannaioni PF. L'abuso di farmaci leciti nei tossicodipendenti da eroina. *Clinica Terapeutica*, 1987; 120 : 183-198.
- 9- Woods JH, Winger G. Abuse liability of flunitrazepam. *J of Clinical Psychopharmacology*, 1997; 17: 1S-57S.