

THE USE OF A COVERED EXPANDABLE METAL STENT FOR THE MANAGEMENT OF ESOPHAGEOTRACHEAL FISTULA RESULTING FROM ESOPHAGEAL CARCINOMA: A CASE REPORT

ÖZEFAGEAL KARSİNOM SONUCU GELİŞEN ÖZEFAGOTRAKEAL FİSTÜL TEDAVİSİNDE KAPLI GENİŞLEYEBİLEN METAL STENT KULLANIMI: BİR OLGU SUNUMU

Sefa GÜLİTER, M.D., Fahri YAKARYILMAZ*, M.D., Bülent DEĞERTEKİN*, M.D.,
Ahmet GÖRGÜL**, M.D.

University of Kırıkkale Faculty of Medicine, Department of Gastroenterology, Kırıkkale-Turkey
SSK Ankara High Education Hospital, Department of Gastroenterology*, Ankara-Turkey
Gazi University Faculty of Medicine, Department of Gastroenterology**, Ankara-Turkey
Gazi Medical Journal 2004; 15: 27-30

SUMMARY: Malignant esophagorespiratory fistula is a rare condition that is difficult to manage. Palliative treatment by surgical bypass is often unjustified, and the use of esophageal stents has been shown to be more appropriate. We describe a 64-year-old man with inoperable esophageal carcinoma presenting with symptoms of an esophagorespiratory fistula. A covered expandable metallic stent was successfully inserted into the esophagus. The patient's symptoms improved dramatically and he survived for 16 months. The use of a covered expandable metal stent is a safe and practical alternative treatment for palliating inoperable esophageal carcinomas in patients with esophagorespiratory fistulas.

Key Words: Esophagorespiratory Fistula, Stent, Esophageal Carcinoma.

INTRODUCTION

Esophagorespiratory fistulas may result from locally advanced esophageal or tracheobronchial malignancies or as a complication of endoluminal palliation (such as radiotherapy, laser ablation, local hyperthermia, photodynamic therapy or esophageal dilatation) of dysphagia due to malignant tumor stenosis (1-3).

Once an esophagoatracheal fistula has developed the patient's condition worsens rapidly due to aspiration pneumonia and malnutrition. As the tumor stage is generally advanced and life expectancy is short, the major interest of any therapeutic procedure in these cases must be a rapid and successful palliation, reducing the

ÖZET: Malign özefagorespiratuvar fistül, tedavisi konusunda zorluklar olan nadir bir hastalıktır. Cerrahi bypass ile palyatif tedavi sıklıkla yapılamaz. Özefageal stentlerin kullanımı daha uygun olarak görülmektedir. Burada 64 yaşında özefagorespiratuvar fistül semptomları ile başvuran inoperabl özofagus karsinomlu bir olguyu sunmaktayız. Kaplı, genişleyebilen metalik bir stent başarılı bir şekilde özefagusu yerleştirildi. Hastanın semptomları hızla düzeldi ve hasta 16 ay yaşadı. Özefagorespiratuvar fistüllü hastalardaki inoperabl özefageal kanserlerin palyatif tedavisinde kaplı özefageal stentlerin kullanılmasını güvenli ve pratik bir alternatif tedavi şeklidir.

Anahtar Kelimeler: Özefagorespiratuvar Fistül, Stent, Özefagus Karsinom.

duration of in-hospital stay at low cost, and a low rate of therapy-induced complications (1-3).

The use of stents has been advocated in the management of esophagoatracheal fistulas. The significant morbidity and mortality of the formerly used cuffed plastic stents (4) and the inherent difficulties with the insertion of rigid stents have been overcome by the new coated expandable stents (5, 6).

We report a case of malignant esophagoatracheal fistula resulting from esophageal carcinoma, which was managed with a covered expandable metal stent.

CASE REPORT

A 64-year-old man was referred with a 4-month history of dysphagia. His history revealed that the dysphagia initially appeared with only solid food intake and with both liquid and solid food intake one month later. The patient had a persistent cough ten days prior to his admittance. The patient also had a history of 10-kg weight loss in the recent four months and treatment of pulmonary tuberculosis eight years previously. On physical examination, he had general weakness and mild dehydration. Laboratory data were within normal limits. His chest X-ray showed nonspecific fibrotic changes in the upper zone of the right lung. Upper gastrointestinal endoscopy revealed an ulcerovegetant infiltrating tumoral mass between 25 and 30 cm from the arcus of the upper teeth; however, we failed to pass the endoscope through the tumor, because the luminal opening was as narrow as 7 mm. We were able to pass a pediatric endoscope through the tumoral mass, which showed no abnormal findings in the distal esophagus or the stomach. Histologic examination of multiple biopsies from the tumor revealed a squamous cell carcinoma of the esophagus. His heavy and persistent cough alerted us to a possible diagnosis of esophagotracheal fistula. The patient began to cough following the intake of a diluted radiopaque solution (Iodine; Guerbet AS, Istanbul). His chest X-ray revealed the bronchogram showing the leak of radiopaque solution into the trachea (Fig. 1). The patient was

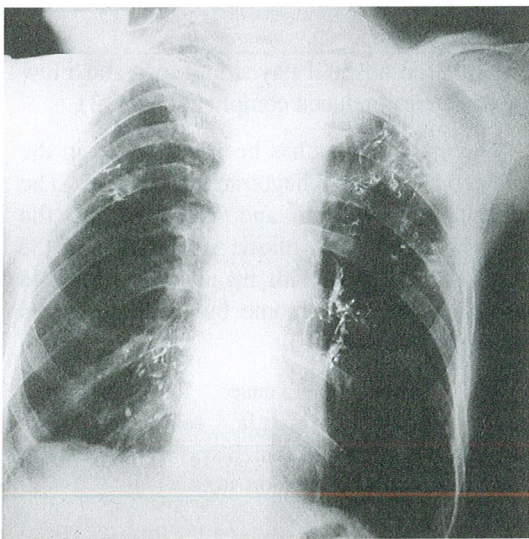


Fig. 1: Chest X-ray showing the bronchogram before the stent replacement.




Fig. 2: Expanded appearance of covered metal stent.

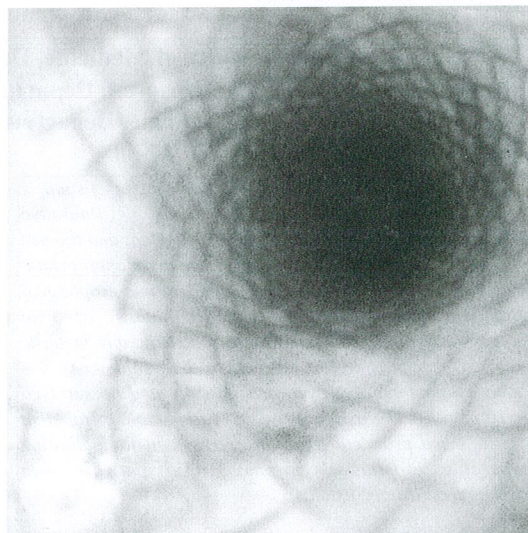


Fig. 3: Endoscopic appearance of the expandable covered metal stent inserted.

inoperable and palliative treatment options were considered. We inserted a polyurethane covered expandable metal (nitinol: nickel-titanium) stent that is flexible in the longitudinal axis with flare stepped heads to prevent migration (Taewoong Medical Co, Seoul, South Korea) 12 cm long and 1.8 cm wide (Fig. 2) by endoscopy into the infiltrating region after dilatation of a lumen of 12.5 mm using Savary Bougies under fluoroscopic control (Fig. 3). The patient tolerated the procedure well and no symptoms of aspiration were observed in the following 48 hours. Serial chest X-rays were performed on the following days and no bronchogram findings were seen on the eighth day of the stent insertion

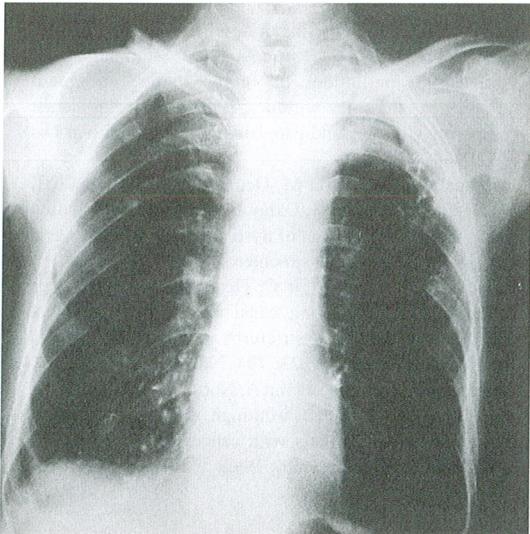


Fig. 4: Disappearance of the bronchogram image on the eighth day of the stent insertion.

(Fig. 4). The patient was discharged from the hospital 10 days after stent insertion and showed no symptoms of aspiration or dysphagia before his death from distant metastases and advanced disease sixteen months later.

COMMENT

The treatment of malignant esophagorespiratory fistulas still represents a challenge in gastroenterology. The associated symptoms, such as heavy coughing, aspiration, dysphagia and malnutrition, are very compromising for these patients performance status, which declines rapidly. Considering the short life expectancy, successful sealing of the fistula ensuring an acceptable quality of life must be the goal of any treatment for these patients.

Routine surgical procedures, like muscle flap repair or palliative resection, are reserved to a minority of selected cases due to the advanced tumor stages (3). In debilitated patients and those with extensive disease the insertion of esophageal stents is an attractive option (1). A recent development in this field has been the self-expanding esophageal metallic stent, which has the advantage of an incidence of complications lower than that of plastic endoprotheses (0% versus 43%, respectively) (7). A further modification of the metallic stent has been the introduction of a polyethylene cover around the stent to prevent tumor ingrowth, which makes it theoretically suitable for treating

esophagorespiratory fistulas (8). There are several features in the design of the covered stent that make it ideal for treating esophagorespiratory fistulas. Its self-expanding nature allows its covered surface to form a tight seal at the site of the fistula. The larger proximal and distal flange and anchoring hooks in its midportion help to prevent stent migration, which may be a cause of recurrent pulmonary soiling (2).

The treatment of esophagorespiratory fistulas with covered expandable stents has been a promising treatment method for the last decade. Wu et al. (8) reported the first series of successful replacement (no signs of aspiration or obstruction) of covered expandable metal stents in eight patients with esophagorespiratory fistulas. After the success of this kind of stent replacement in patients with esophagorespiratory fistulas, there have been reports of stent replacements in similar cases (2, 3, 9, 10-12). In Turkey, Dobrucal et al. (13) in one patient and Sarper et al. (14) in nine of ten patients have also reported the replacement of covered expandable metal stents in patients with malignant esophago-tracheal fistulas.

Recurrent respiratory contamination may occur due to the inability to seal the fistula proximally or as a result of stent migration. In addition, the use of plastic endoprotheses may result in complications including perforation, stent migration, hemorrhage, and obstruction (15). We did not observe any complications in our case.

In this article, we report a case of squamous cell carcinoma of the esophagus with esophagorespiratory fistula showing symptoms of aspiration. A covered expandable metal stent was successfully inserted, and the patient was able to take food 48 hours after the procedure. The patient lived symptom-free until his death from distant metastases and advanced disease sixteen months later.

The use of covered expandable metal stents for palliating esophagorespiratory fistulas is a safe and easily applicable technique ensuring a good quality of the remaining span of life. Due to the low rate of complications and the quick relief from symptoms a marked reduction in the duration of in-hospital stay is achieved.

Correspondence to: Sefa GÜLİTER, M.D.
Ekim Sokak Ece Apt 5/4
06130 ANKARA - TÜRKİYE
Phone: 318 - 225 24 80 / 211
312 - 316 36 63
E-mail: sguliter@hotmail.com

REFERENCES

1. Burt M, Diehl W, Martini N, Bains MS, Ginsberg RJ, McCormack PM, Rusch VW. Malignant esophagorespiratory fistula: management options and survival. *Ann Thorac Surg* 1991; 52: 1222-1228.
2. Wong K, Goldstraw P. Role of covered esophageal stents in malignant esophagorespiratory fistula. *Ann Thorac Surg* 1995; 60: 199-200.
3. Tomaselli F, Maier A, Sankin O, Woltsche M, Pinter H, Smolle-Juttner FM. Successful endoscopic sealing of malignant esophageotracheal fistulae by using a covered self-expandable stenting system. *Eur J Cardiothorac Surg* 2001; 20: 734-738.
4. Hordijk ML, Dees J, van Blankenstein M. The management of malignant esophagorespiratory fistulas with cuffed prosthesis. *Endoscopy* 1990; 22: 241-244.
5. Ell C, May A, Hahn EG. Gianturco-Z stents in the palliative treatment of malignant esophageal obstruction and esophageotracheal fistula. *Endoscopy* 1995; 27: 495-500.
6. Cook TA, Dehn TCB. Use of covered expandable metal stents in the treatment of oesophageal carcinoma and tracheo-oesophageal fistula. *Br J Surg* 1996; 83: 1417-1418.
7. Knyrim K, Wagner HJ, Bethge N, Keymling M, Vakil N. A controlled trial of an expansile metal stent for palliation of esophageal obstruction due to inoperable cancer. *N Engl J Med* 1993; 329: 1302-1307.
8. Wu WC, Katon RM, Saxon RR, Barton RE, Uchida ET, Keller FS, Rosch J. Silicone-covered self-expandable metallic stents for the palliation of malignant esophageal obstruction and esophagorespiratory fistulas: experience in 32 patients and a review of the literature. *Gastrointest Endosc* 1994; 40: 22-33.
9. Mohammed S, Moss J. Palliation of malignant tracheo-oesophageal fistula using covered metal stents. *Clin Radiol* 1996; 51: 42-46.
10. Morgan RA, Ellul JP, Denton ER, Glynos M, Mason RC, Adam A. Malignant esophageal fistulas and perforations: management with plastic-covered metallic endoprotheses. *Radiology* 1997; 204: 527-532.
11. May A, Ell C. Palliative treatment of malignant esophagorespiratory fistulas with Gianturco-Z stents. A prospective clinical trial and review of the literature on covered metal stents. *Am J Gastroenterol* 1998; 93: 532-535.
12. Ricioni ME, Shah SK, Tringali A, Ciletti S, Mutignani M, Perri V, Zuccala G, Coppola R, Costanmagna G. Endoscopic palliation of unresectable malignant oesophageal strictures with self-expanding metal stents: comparing Ultraflex and Esophacoil stents. *Dig Liver Dis* 2002; 34: 356-363.
13. Dobrucalı A, Özgüroğlu M, Demir G, Karahasanoğlu T, Uzunismail H, Cebeci H, Oktay E, Dinç İ. Self expanding metal stents for palliation of dysphagia due to esophageal malignancies. *Turk J Gastroenterol* 1999; 10: 18-23.
14. Sarper A, Oz N, Cihangir C, Demircan A, Isin E. The efficacy of self-expanding metal stents for palliation of malignant esophageal strictures and fistulas. *Eur J Cardiothorac Surg* 2003; 23: 794-798.
15. Cusumano A, Ruol A, Segalin A, Norberto L, Baessato M, Tiso E, Peracchia A. Push-through intubation: effective palliation in 409 patients with cancer of the esophagus and cardia. *Ann Thorac Surg* 1992; 53: 1010-1014.