

# INVASIVE EEG MONITORING IN CHILDREN: A REPORT OF THREE CASES

## ÇOCUKLARDA İNVAZİV EEG MONİTÖRİZASYONU: ÜÇ OLGU RAPORU

Çetin OKUYAZ, M.D., Semiha KURT\*, M.D., Ayşe KARATAŞ\*\*, M.D., Gülnihal KUTLU\*, M.D., Kürşad AYDIN, M.D., Ayşe SERDAROĞLU, M.D., Erhan BİLİR\*, M.D., Atilla ERDEM\*\*, M.D.

Gazi University, Faculty of Medicine, Departments of Pediatric Neurology and Neurology\*, Ankara-Turkey  
Ankara University, Faculty of Medicine, Department of Neurosurgery\*\*, Ankara-Turkey  
Gazi Medical Journal 2003; 14: 45-49

**SUMMARY:** Surgery is recommended for children with localization related epilepsy that is intractable to drug therapy. For a successful surgical outcome, the precise localization of the epileptogenic cortex should be determined. Several diagnostic techniques may be used in order to achieve this goal; however, EEG is still the main method. In some patients scalp EEG is not capable of localizing epileptogenic focus or it is discordant with other diagnostic measures. In such patients, invasive EEG monitoring should be performed. In this article, we emphasize the importance of invasive EEG monitoring in three patients with medically refractory epilepsy. To our knowledge, these cases are the first children evaluated by invasive EEG monitoring in a university hospital in Turkey.

**Key Words:** Invasive EEG Monitoring, Children, Medically Refractory Epilepsy.

### INTRODUCTION

Antiepileptic drugs control seizures in most patients with epilepsy, whereas about 25% of epileptic patients fail to gain complete control over their seizures, despite trials of multiple medications (1). This group of epilepsy is defined as medically refractory epilepsy. In children with medically refractory localization related epilepsy, seizures generally originate from a particular area of the brain and some of these patients may benefit from surgical treatment for epilepsy. Determination of the precise localization of the epileptogenic focus or zone is imperative for planning surgical treatment in such cases of

**ÖZET:** Çocukluk çağının ilaç tedavisine dirençli parsiyel epilepsilerinin tedavisinde cerrahi tavsiye edilmektedir. Ancak cerrahinin başarılı sonuçlar verebilmesi için epileptojenik korteksin yeri tam olarak belirlenmelidir. Bu amaç için çeşitli tanı yöntemleri kullanılmaktadır, ancak EEG hala ana metoddur. Bazı olgularda skalp EEG epileptojenik korteksin yerini belirlemede yetersiz kalabilir ya da diğer tanı metodlarının sonuçları ile uyumlu olmayabilir. Bu tür olgularda invaziv EEG monitörizasyonu yapılmalıdır. Bu yazıda ilaç tedavisine dirençli parsiyel epilepsili üç olgu nedeniyle invaziv EEG monitörizasyonunun önemini vurguladık. Bizim bilgilerimize göre olgularımız Türkiye'de bir üniversite hastanesinde invaziv EEG monitörizasyonu uygulanan ilk çocuk olgulardır.

**Anahtar Kelimeler:** Invaziv EEG Monitörizasyonu, Çocuk, İlaça Dirençli Epilepsi Cerrahi.

uncontrolled epilepsy (1). Although noninvasive evaluation is conclusive alone in most patients, some patients with medically refractory complex partial seizures cannot be evaluated clearly by noninvasive tests despite improvements in these techniques. EEG recording with invasive electrodes is required if scalp EEG is not capable of localizing the epileptogenic focus and/or if there is a discordance between seizure semiology, scalp EEG, neuroradiology and functional imaging (1-3). Depth and/or subdural electrodes are employed to localize the focus in these patients. We report three cases with complex partial seizures diagnosed as temporal lobe

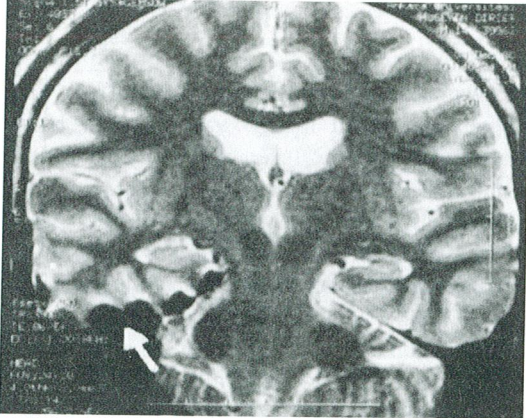


Fig. 3: MRI shows the electrodes in the right subtemporal region.

After the patient was taken to the telemetry room a reference electrode was affixed to the vertex with collodion. The EEG recordings were done with referential or bipolar montages depending on the location of the focus and previous recordings. The patients received antibiotics intravenously shortly prior to electrode implantation and were maintained on intravenous antibiotic therapy every 12 hours until the electrodes were withdrawn. No complications were seen during electrode placement, monitoring and electrode extracting.

Video EEG monitoring was continued until the patients underwent 3 spontaneous typical seizures. The electrodes were removed percutaneously in the patient's room after sufficient data were obtained.

## DISCUSSION

Twenty-five percent of children with epilepsy continue to experience seizures despite appropriate medical management and such children are considered to have medically refractory epilepsy (1). These type of epileptic patients may benefit from surgical treatment including hemispherectomy, corpus callosotomy, multiple subpial resections and focal cortical resections of the temporal and extratemporal lobes such as anterior temporal lobectomy and selective amygdalohippocampectomy (1). A successful outcome of epilepsy surgery is generally defined as a seizure-free state without

neurologic deficit. Determining the precise localization of the epileptogenic zone is necessary for a successful surgical outcome. Many diagnostic methods including ictal and interictal scalp video EEG recordings, MRI, positron emission tomography (PET), single photon emission computerized tomography (SPECT) and interictal magnetoencephalography can be used for localizing the epileptogenic zone (1,4-6). If the clinical, neuropsychological, ictal and interictal EEG and radiological data are all concordant, and indicate the same area as the epileptogenic zone, epilepsy surgery can be performed. However, if there is a discordance between the findings from different diagnostic features, further evaluation is needed (1-3,7). Invasive EEG monitoring using subdural strip, grid and depth electrodes provides further information about the epileptogenic cortex despite carrying some risks like infection, bleeding and tissue damage (8). Diehl et al. suggested that indications of invasive EEG dramatically decreased since the introduction of high resolution MRI (9). It is reported that invasive EEG was required in 27% of patients with intractable TLE for successful surgical outcomes (10). Kim et al. showed that invasive EEG was also valuable in the evaluation of intractable extratemporal lobe epilepsies (11). Lee et al. reported that ictal scalp EEG could determine epileptogenic focus precisely in only 52% of 86 patients with intractable TLE who subsequently underwent invasive study and resective surgery (12). We used invasive EEG monitoring in three patients with complex partial seizures that were probably originating from the temporal lobe. In patient 1, scalp ictal EEG had not indicated the epileptogenic zone precisely. Invasive EEG monitoring was needed because of the absence of anatomo-electro-clinical correlation. Invasive ictal EEG monitoring showed that seizures were generating from the left temporal lobe. In patient 2, ictal and interictal scalp EEG revealed a lateralized epileptogenic focus in the left hemisphere, but localization could not be determined. Invasive EEG monitoring was performed to ascertain whether the epileptogenic focus was localized in the temporal lobe or not. It showed the epileptogenic focus to be in left temporal neocortical structures. In patient 3, abnormal ictal and interictal scalp EEG findings were on both the left and right

temporal lobes. Invasive EEG monitoring was performed for further evaluation, but invasive EEG did not provide any further information. EEG monitorization with depth electrodes was planned. Invasive EEG were extremely valuable in the presurgical evaluation of our patients. We did not observe any complications during the placement of invasive electrodes, video EEG monitoring and after extracting the electrodes. In this article, we reported three cases to emphasize the importance of invasive EEG in children with medically refractory epilepsy, especially in the absence of anatomo-electro-clinical correlation.

In conclusion, despite improvements in noninvasive EEG technology, high resolution cranial MRI and functional imaging methods, some patients with localization-related medically refractory epilepsy cannot be evaluated clearly when determining surgical treatment. If there is a discordance between scalp EEG, MRI, seizure semiology or if scalp EEG data is inconclusive, invasive EEG monitoring should be performed. In certain patients invasive EEG monitoring is very helpful for presurgical evaluation.

**Correspondence to:** Çetin OKUYAZ, M.D.  
4. cad., Silistre Apt, No: 79/13  
Bahçelievler  
06490 ANKARA - TÜRKİYE  
Phone: 312 - 223 60 77  
Fax: 312 - 215 01 43  
e-mail: drokuyaz@hotmail.com

#### REFERENCES

1. Snead OC. Surgical treatment of medically refractory epilepsy in childhood. *Brain Dev* 2001; 23: 199-207.
2. Jayakar P. Invasive EEG monitoring in children: when, where, and what?. *J Clin Neurophysiol* 1999; 16: 408-418.
3. Blume WT. Current trends in electroencephalography. *Curr Opin Neurol* 2001; 14: 193-197.
4. Weil S, Noachtar S, Arnold S, Yousry TA, Winkler PA, Tatsch K. Ictal SPECT differentiates between temporal and extratemporal epilepsy: confirmation by excellent postoperative seizure control. *Nucl Med Commun* 2001; 22: 233-237.
5. Minassian BA, Otsubo H, Weiss S, Elliot I, Rutka JT, Snead OC. Magnetoencephalographic localization in epilepsy surgery: comparison with invasive intracranial electroencephalography. *Ann Neurol* 1999; 46: 627-633.
6. Zupanc ML. Neuroimaging in the evaluation of children and adolescents with intractable epilepsy. *Pediatr Neurol* 1997; 17: 111-121.
7. Zumsteg D, Wieser HG. Presurgical evaluation: current role of invasive EEG. *Epilepsia* 2000; 41: 55-60.
8. Sperling MR. Clinical challenges in invasive monitoring in epilepsy surgery. *Epilepsia* 1997; 38: 6-12.
9. Diehl B, Luders HO. Temporal lobe epilepsy: When are invasive recordings needed? *Epilepsia* 2000; 41: 61-74.
10. Blume WT, Hwang PA. Pediatric candidates for temporal lobe epilepsy surgery. *Can J Neurol Sci* 2000; 27: 14-19.
11. Kim SK, Wang KC, Hwang YS, Kim KJ, Kim IO, Lee DS, Yi Y, Cho BK. Pediatric intractable epilepsy: the role of presurgical evaluation and seizure outcome. *Childs Nerv Syst* 2000; 16: 278-285.
12. Lee SK, Kim JY, Hong KS, Nam HW, Park SH, Chung CK. The clinical usefulness of ictal surface EEG in neocortical epilepsy. *Epilepsia* 2000; 41: 1450-1455.