

CASE REPORTS

BILATERAL DIVIDED PIRIFORMIS MUSCLE TOGETHER WITH THE HIGH DIVISION OF THE SCIATIC NERVE

SİYATİK SİNİRİN YÜKSEK AYRILMASI İLE BİRLİKTEKLİ İKİ PARÇALI PİRİFORM KAS

Deniz DEMİRÜREK, M.D., Alp BAYRAMOĞLU, M.D., Mine ERBİL, M.D.,
M. Mustafa ALDUR, M.D., Mustafa F. SARGON M.D.

Hacettepe University, Faculty of Medicine, Department of Anatomy, Ankara-Turkey
Gazi Medical Journal 2002; 13: 41-44

SUMMARY : We report a case with divided piriformis muscle together with the sciatic nerve dividing high and the common fibular nerve passing between the two divisions of the piriformis muscle in both gluteal regions. Regarding the clinical syndrome of the piriformis muscle; this should be taken into consideration by clinicians.

Key Words: Piriformis Muscle, Sciatic Nerve, Variation, Piriformis Syndrome.

INTRODUCTION

The piriformis muscle is located on the posterior aspect of the hip joint, inferior to gluteus minimus muscle. It arises from the anterolateral surface of sacrum, issues from pelvis via the greater sciatic notch and attaches to the greater trochanter of femur. The piriformis muscle provides the key to the arrangement of the nerves and vessels in the gluteal region. During embryological development, the nerves contributing to the lower limb form two plexuses, a lumbar and a sacral, at the base of the wide limb bud. The elements from each plexus grow out into the limb and then divide into dorsal and ventral components. The large dorsal component of the sacral plexus is the common fibular nerve and the ventral component is the tibial nerve. These two components go downward close

ÖZET : Bu makalede musculus piriformis'in iki parçalı olduğu ve bu iki parçanın arasından nervus ischiadicus'un nervus fibularis communis dalının geçtiği bir vaka sunulmaktadır. İki taraflı saptanan bu varyasyon, piriformis sendromu tanısında göz önünde bulundurulmalıdır.

Anahtar Kelimeler: Musculus Piriformis, Nervus İchiadicus, Varyasyon, Piriformis Sendromu.

together to form the sciatic nerve (1).

The sciatic nerve emerges from the greater sciatic foramen and generally passes inferior to the piriformis muscle. The nerve divides into its common fibular and tibial branches approximately halfway or more down the thigh.

The relationship between the sciatic nerve and the piriformis muscle has been studied by many authors and several variations have been detected (2-6). This study describes a bilateral anatomical variation of the piriformis muscle and sciatic nerve, which has not previously been reported in the literature.

CASE REPORT

In the right and left gluteal regions of a 57-year old male cadaver, a combined variation was detected. After the removal of the skin and fatty

This study has been presented as an oral communication in the 5th European Association of Clinical Anatomy Congress Constanta, Roumania, June 3-5, 1999.

tissue, the gluteus maximus muscle was exposed and removed. The piriformis muscle was observed as being divided into two portions. The upper part was larger and was separated from the lower part by the common fibular nerve piercing the muscular fascia. The tibial nerve emerged below the lower part of the piriformis muscle (Fig. 1 and 2).

In the right and left gluteal regions of this cadaver, the upper portion of the piriformis

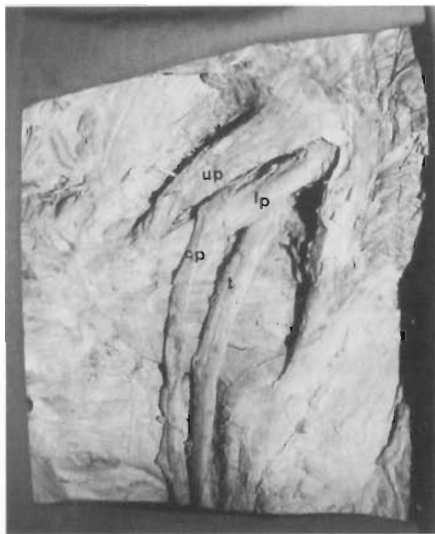


Fig. 1: Photograph showing divided piriformis muscle and the high dividing sciatic nerve passing between the two portions of the piriformis muscle in the left gluteal region.



Fig. 2: Photograph showing divided piriformis muscle and the high dividing sciatic nerve passing between the two portions of the piriformis muscle in the right gluteal region.

muscle originated from the anterior surface of the sacrum and the lower portion from the lower part of the anterior surface of the sacrum and the sacrotuberous ligament. The insertions of these two portions were to the greater trochanter of the femur. These two portions were innervated by the branches emerging from the sacral plexus. Interestingly in this case, all the variations were observed bilaterally (Fig. 3).

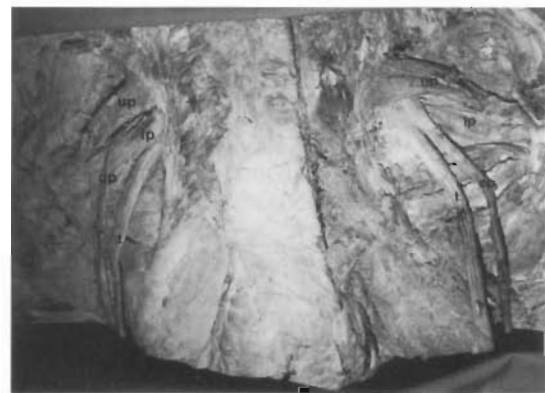

Fig. 3: Photograph showing divided piriformis muscle and the high dividing sciatic nerve passing between the two portions of the piriformis muscle bilaterally.

- up* : Upper portion of piriformis muscle
- lp* : Lower portion of piriformis muscle
- cp* : Common fibular nerve
- t* : Tibial nerve
- gm*: Gluteus medius muscle
- gs*: Superior gemellus muscle
- oi*: Obturator internus muscle
- gi*: Inferior gemellus muscle.

In the sacral plexus the sciatic nerve was formed by the ventral rami of L4 to S2 that converge on the anterior surface of the piriformis muscle.

The common fibular nerve coursed along the medial border of the biceps femoris muscle at the apex of the popliteal fossa. The tibial nerve coursed in the middle of popliteal fossa and the sural nerve was formed by lateral and medial sural cutaneous nerves below the popliteal fossa.

The gemellus superior, obturator internus, gemellus inferior, quadratus femoris muscles; gluteal and pudendal vessels and the pudendal

nerve were observed as normal anatomical structures on both sides of the cadaver.

All these muscles were innervated by the branches of the sacral plexus.

DISCUSSION

During embryological development, motor nerve fibers in the spinal cord begin to appear at the end of the fourth week. The nerve fibers arise from cells in the basal plates of the developing spinal cord and emerge as a continuous series of rootlets along its ventrolateral surface. The fibers destined for a particular developing muscle group become arranged in a bundle forming a ventral nerve root. The dorsal nerve root is formed by axons of neural crest cells that migrate to the dorsolateral aspect of the spinal cord where they differentiate into the cells of the spinal ganglion. The distal processes of spinal ganglion cells grow toward the ventral nerve root and eventually join with it to form a spinal nerve. Immediately after being formed, a mixed spinal nerve divides into dorsal and ventral primary rami. The dorsal primary ramus, the smaller division, innervates the dorsal axial musculature, vertebrae, posterior intervertebral joints, and part of the skin of the back. The ventral primary ramus, the major division of each spinal nerve, contributes to the innervation of the limbs and ventrolateral parts of the body wall. The major nerve plexuses are formed by ventral primary rami. The nerves contributing to the lower limb correspond to those at the level of the originally wide limb bud. They form two plexuses, a lumbar and a sacral, at the base of this bud and as the elements from each plexus grow out into the limb they become subdivided into the dorsal and ventral components, for the dorsal and ventral musculature. The large dorsal component of the sacral plexus is the common fibular nerve and the ventral component is the tibial nerve. These two components go downward close together to form the sciatic nerve (1).

The limbs begin to appear toward the end of the fourth week as slight elevations of the ventrolateral body wall. The upper limb buds develop about two days before the lower limb buds. The tissues of the limb buds are derived from two main sources- somatic mesoderm and ectoderm. The apical ectodermal ridge (AER) exerts an inductive influence on the limb mesenchyme that promotes growth and

development of the limbs. The limb buds elongate by proliferation of the mesenchyme within them. Initially, the developing limbs are directed caudally; later, they project ventrally, and finally, they rotate on their longitudinal axes. When the limbs descend, they carry their nerves with them; this explains the oblique course of the nerves of the brachial and lumbosacral plexuses (1).

The relationship between the sciatic nerve and the piriformis muscle may show several variations. Sappey (as cited by Pecina; 1979) was the first to find the piriformis muscle divided into two portions between which one portion of the sciatic nerve may pass (7). Mouret found that in the case of high division of the sciatic nerve, the common fibular nerve passes through the piriformis muscle (8). Beaton and Anson reported the incidence of the divisions of the sciatic nerve passing between and below the heads of the muscle as 11.7 % (3). Parsons and Keith found this ratio to be 12.3% (9). Pecina reported the ratio as 20.77% of the 130 specimens of the lower extremities (7). Berkol et al. emphasized that sex and side do not play an important role in the passage incidence of the common fibular nerve through the piriformis muscle (10). Arifoğlu et al. reported a case with double gemellus superior muscle and the common fibular nerve passing through the double piriformis muscle (11). However, we could not find a study describing divided piriformis muscle together with the common fibular nerve passing through the two portions of the muscle bilaterally.

The relation described could be explained based on the facts that occur during embryological development. The common fibular and tibial divisions of the sciatic nerve may separate from each other at their origins instead of halfway or more down the thigh and take different courses into the buttock, and the piriformis muscle may be divided into two parts by one or both components of the sciatic nerve (1).

The positional relationship between the piriformis muscle and sciatic nerve may cause piriformis syndrome, a clinical entity characterized by sciatica due to the compression of the sciatic nerve by the piriformis muscle. This syndrome may occur as a postoperative complication (12), but generally perforation of

the piriformis muscle by the sciatic nerve or its divisions is held responsible for the sciatica (13-16).

In our case the bilateral relationship of the sciatic nerve and the divided piriformis muscle could lead to compression of the nerve which may cause the piriformis syndrome.

The diagnosis of the piriformis syndrome is primarily clinical, as it is the reason for non definitive investigations which have been reported. MR imaging and CT of the pelvic region can be a reasonable alternative for visualizing the piriformis muscle (17-19).

In the differential diagnosis in cases of sciatica, lower extremity weakness and pain, the piriformis syndrome should be taken into account by the clinicians. Detailed history taking, a careful physical examination, and versatile use of CT and MR imaging can lead to an early, accurate diagnosis and proper treatment.

Correspondence to: Deniz DEMİRYÜREK, M.D.
Hacettepe Üniversitesi Tıp Fakültesi
Anatomi Anabilim Dalı
06100 ANKARA - TÜRKİYE
Phone : 312 - 305 23 59
Fax: 312 319 71 69
E-mail: ddeniz@tr.net

REFERENCES

1. Moore KL, Persaud TVN. The Developing Human. 5th ed. Philadelphia : WB Saunders Company; 1993.
2. Trotter M. The relation of the sciatic nerve to the piriformis muscle in American whites and negroes. *Anat Rec* 1932; 52: 32.
3. Beaton LE, Anson BJ. The relation of the sciatic nerve and of its subdivisions to the piriformis muscle. *Anat Rec* 1937; 70: 1-5.
4. Ming-Tzu P. The relation of the sciatic nerve to the piriformis muscle in Chinese. *Am J Phys Anthropol* 1941; 28: 375.
5. Chiba S. Multiple positional relationships of nerves arising from sacral plexus to the piriformis muscle in humans. *Kaibogaku Zasshi (Acta Anat Nippon)* 1992; 67: 691-724.
6. Lee CS, Tsai TL. The relation of the sciatic nerve to the piriformis muscle. *J Formosan Med Assoc* 1974; 73: 75-80.
7. Pecina M. Contribution to the etiological explanation of the piriformis syndrome. *Acta Anat* 1979; 105: 181-187.
8. Mouret J. Rapports des muscles pyramidaux avec le nerf sciatique. *Montpell Méd* 1893; 2:230-233.
9. Parsons FG, Keith A. Sixth annual report of the committee of collective investigation of the Anatomical Society of Great Britain and Ireland. *J Anat and Physiol* 1896; 31: 31.
10. Berkol N, Mouchet A, Gögen H. Note sur le niveau de bifurcation du grand nerf sciatique. *Ann d'Anat Pathol et d'Anat Norm Med* 1935; 12: 596-600.
11. Arifoglu Y, Sürücü HS, Sargon MF, Tanyeli E, Yazar F. Double superior gemellus together with double piriformis and high division of the sciatic nerve. *Surg Radiol Anat* 1997; 19: 407-408.
12. Brown JA, Braun MA, Namey TC. Piriformis syndrome in a 10-year old boy as a complication of operation with the patient in the sitting position. *Neurosurg* 1988; 23: 117-119.
13. Hallin RP. Sciatic pain and the piriformis muscle. *Postgrad Med* 1983; 74: 69-72.
14. Pfeifer T, Fitz WF. The piriformis syndrome. *Z Orthop* 1989; 127: 691-694.
15. Chen WS. Bipartite piriformis muscle: An unusual cause of sciatic nerve entrapment. *Pain* 1994; 58: 269-272.
16. Sayson SC, Ducey JP, Maybrey JB, Wesley RL, Vermilion D. Sciatic entrapment neuropathy associated with an anomalous piriformis muscle. *Pain* 1994; 59: 149-152.
17. Lanzieri CF, Hilal SK. Computed tomography of the sacral plexus and sciatic nerve in the greater sciatic foramen. *Am J Radiol* 1984; 143:165-168.
18. Barton PM. Piriformis syndrome: A rational approach to management. *Pain* 1991; 47: 345-352.
19. Rossi P, Cardinali P, Serrao M, Parisi L, Bianco F, De Bac S. Magnetic resonance imaging findings in piriformis syndrome: a case report. *Arch Phys Med Rehabil* 2001; 82: 519-521.