

## CASE REPORTS

# REPAIR OF URETERAL MUCOSAL INVAGINATION DUE TO URETEROSCOPIC LITHOTRIPSY: A CASE REPORT

Hasan BİRİ, M.D., Kenan İSEN, M.D., Bora KÜPELİ, M.D., Zafer SINIK, M.D.,  
Nuri DENİZ, M.D., Turgut ALKIBAY, M.D.

Gazi University, Faculty of Medicine, Department of Urology, Ankara, Turkey  
Karaelmas University, Faculty of Medicine, Department of Urology, Zonguldak, Turkey  
Gazi Medical Journal 1998; 9 : 172-174

**SUMMARY** : A 31-year-old woman presented with haematuria and dysuria. A left lower ureteral calculus was identified at intravenous urography. Extracorporeal shock wave lithotripsy (SWL) remained unsuccessful, as well as ureterorenoscopy with ultrasonic lithotripsy. Retrieval of the stone fragment resulted in ureteral injury with avulsion of the ureteral mucosa to the bladder. We report this unusual complication of ureterorenoscopy in the management of distal ureteral calculi, and the technique of surgical correction of such a complication is described.

**Key Words**: Ureteral Calculi, Endoscopy, Ureter, Postoperative Complications.

## INTRODUCTION

The current treatment modalities in the management of lower ureteral calculi are SWL or ureteroscopic techniques. Ureteroscopic removal of stone fragments may be essential when SWL is unsuccessful. However, ureteroscopic management could cause some complications, such as ureteral tearing or perforation (1, 2). We report a case of an unusual complication of ureteroscopic management of lower ureteral calculi after unsuccessful SWL treatment.

## CASE REPORT

A 31-year-old woman presented with haematuria, dysuria, and pollacuria. Physical examination revealed slight tenderness on the suprapubic region. Urine samples showed microscopic haematuria and pyuria; however, urine culture yielded no significant colonization. A 1x1.4 cm lower ureteral calculus was diagnosed at plain abdominal x-ray and intravenous urography (IVU).

IVU also revealed mild proximal dilatation on the same side (Fig. 1A, B).

SWL was planned and 3000 shock waves were performed twice with Siemens Vithostar Plus (Germany) at 19 kV. Three weeks later, ureteroscopic management was decided because of unfragmentation of the stone. Under general anaesthesia, 9.5 Fr ureteroscope was inserted into the bladder. A 5 F ureteral catheter was placed in the ureter prior to insertion of the ureteroscope. After identification of the stone, ultrasonic lithotripsy was performed and fragmentation was achieved. An attempt was made to retrieve a relatively large fragment (0.6 x 0.8 cm) with a ureteroscopic stone forceps. This manipulation resulted in splitting and the avulsion of the last 4 cm of lower ureteral mucosa into the bladder through the ureteral orifice (Fig. 2A). Reversion of this inverted mucosa into the ureter was attempted by endoscopic route; however, this procedure failed because of the length of invaginated mucosal segment. Thus, the

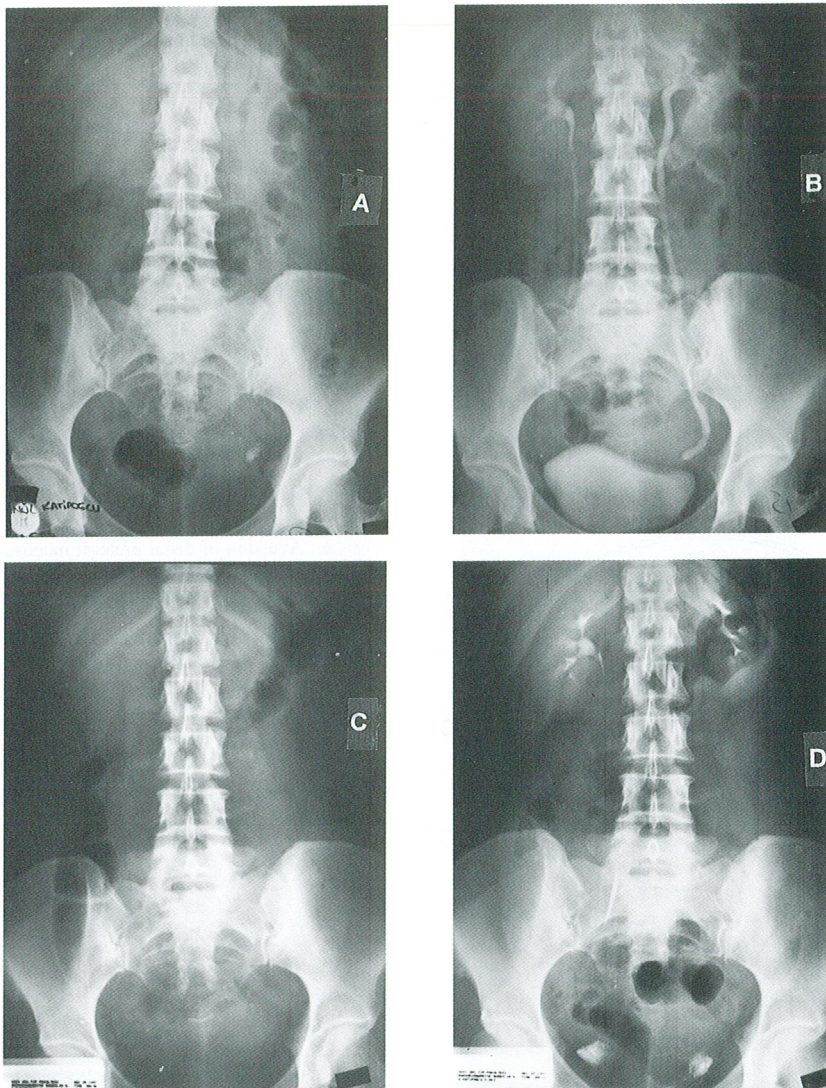


Fig - 1 : Preoperative KUB (Kidney-Ureter-Bladder) (A) and IVU (B), postoperative 3rd month KUB (C) and IVU (D) of the same patient.

patient underwent open surgery in order to correct ureteral injury. After a modified Gibson incision, the bladder was opened. A 1 cm ureteral incision was performed and an ureteral catheter was inserted into the bladder through this hole. The stripped mucosa was tied to the catheter and withdrawal of the catheter placed the mucosa in the original location (Fig. 2B). A 6 F double-j catheter was placed (Fig. 2C).

An IVU was obtained after the withdrawal of the double-j catheter on the third week. No postoperative stricture or dilatation was determined (Fig. 1C, D).

#### DISCUSSION

Ureteroscopy with the rigid ureteroscope is now an integral part of the urologic armamentarium in the management of patients with ureteral calculi. Although it is an effective and less invasive method, serious complications such as tearing of ureteral mucosa, perforation or avulsion of the ureter can sometimes be seen (1, 2). In our case, extracting a stone fragment with a ureteroscopic stone forceps after ultrasonic lithotripsy caused severe ureteral mucosal injury of the distal end. The mucosa inverted from the ureteral orifice, adhering to the stone fragment. After noticing the avulsion, an attempt was made to correct this endoscopically; however, the long inverted mucosa prevented the

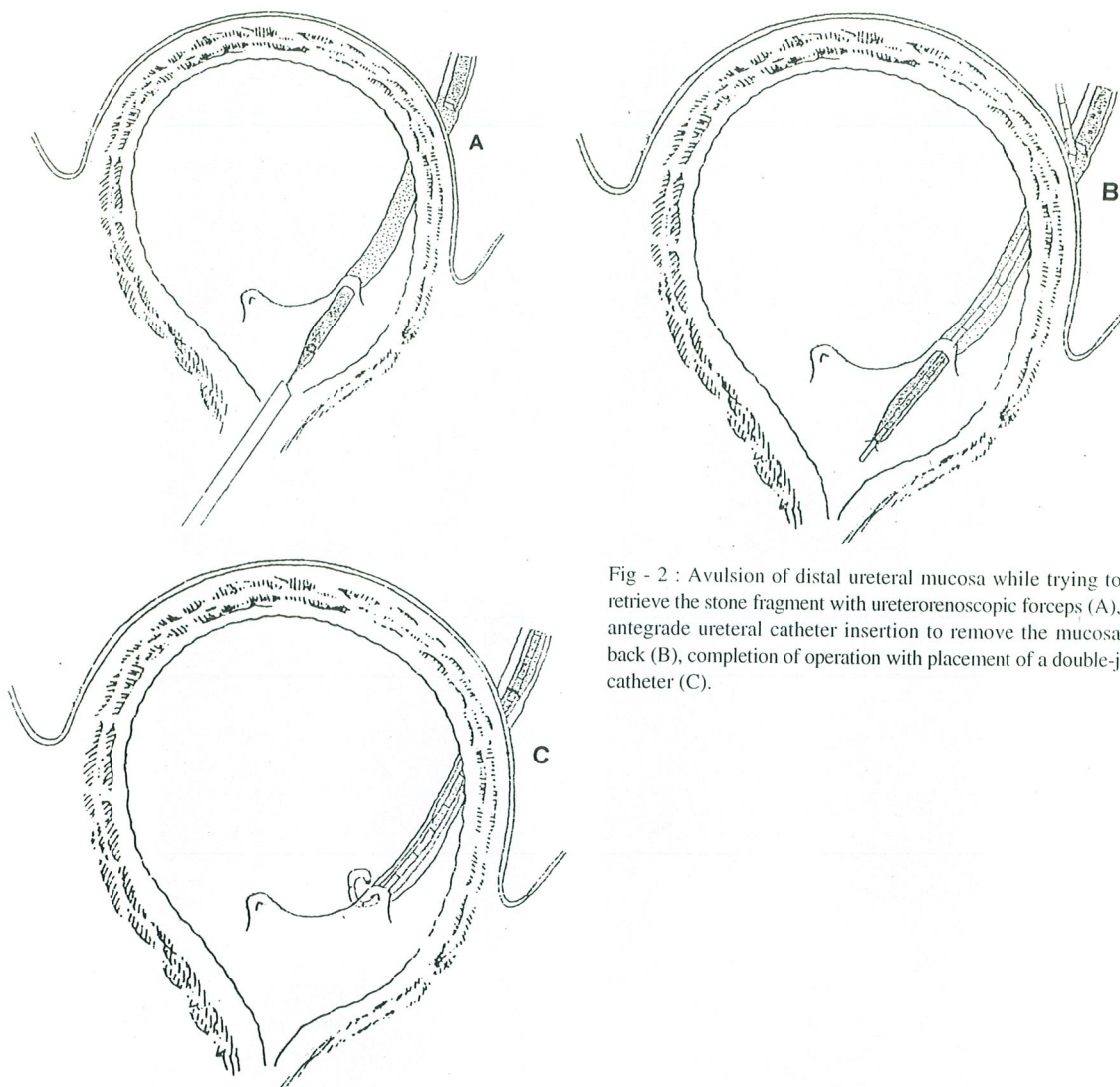


Fig - 2 : Avulsion of distal ureteral mucosa while trying to retrieve the stone fragment with ureterorenoscopic forceps (A), antegrade ureteral catheter insertion to remove the mucosa back (B), completion of operation with placement of a double-j catheter (C).

proper ureteroscopic manipulation. Although the correction of such complications with endoscopic techniques are feasible and less invasive, the length of inverted mucosal segment made this procedure unsuccessful. Therefore, we corrected the injury via open surgery.

Such a complication was not found in the literature. Although it is a rare complication, it can cause serious results such as ureteral stricture. We thought that both the edema formation due to previous SWL applied to the lower ureter and the thermal effect of ultrasonic lithotripsy would have caused this mucosal injury (3). To avoid such complications, it should be remembered that patients who had previous SWL treatments are at risk for such problems and must be treated carefully in order to minimize the possibility of mucosal tearing.

Correspondence to : Dr.Kenan İSEN  
Kenedi Cad. 34 / 6  
Kavaklıdere  
06660 ANKARA - TÜRKİYE  
Phone : 312 - 214 10 00 / 6232

#### REFERENCES

1. Chang R, Marshall FF : Management of ureteroscopic injuries. J Urol 1987; 137 : 1132-1135.
2. Flam TA, Malone MJ, Roth RA : Complications of ureteroscopy. Urol Clin North Am 1988; 15 : 197-102.
3. Huffman JL, Bagley DH, Schoenberg HW, Lyon ES : Transurethral removal of large ureteral and renal pelvic calculi using ureteroscopic ultrasonic lithotripsy. J Urol 1983; 130 : 31-35.