

AN UNUSUAL FOREIGN BODY IN THE BLADDER

Bora KÜPELİ, M.D., Kenan İSEN, M.D., Nuri DENİZ, M.D., Gökalp BİLİCİ, M.D.,
İbrahim BOZKIRLI, M.D.

Gazi University, Faculty of Medicine, Department of Urology, Ankara, Turkey
Gazi Medical Journal 1998; 9 : 181-182

SUMMARY : *A plastic-coated copper wire forming a nidus for stone formation was found in the bladder of a 19-year-old man. The patient presented with dysuria, intermittent hematuria, and recurrent urinary tract infections. The foreign body was removed via open surgery.*

Key Words : *Bladder, Foreign Bodies, Urinary Tract Infections, Recurrence.*

INTRODUCTION

Foreign bodies of the bladder are generally inserted by the patient himself during masturbation or sexual intercourse (1). Most of the patients are aware of the incident and seek medical care. However, some patients, especially with psychiatric disorders, may forget the incident and the foreign body can remain in the urethra or bladder for several years. We report here such a case where a copper wire had been inserted and remained in the bladder for about 6 years.

CASE REPORT

A 19-year-old man presented with dysuria and intermittent hematuria. History revealed that a plastic-coated copper wire had been inserted into the urethra by the patient himself and concealed for about 6 years. During that period, the patient has been treated several times for recurrent urinary infection and psychiatric disorders before presenting at our clinic. Urine examination showed severe pyuria and the culture yielded significant colonies of *Escherichia coli*. A plain abdominal x-ray showed a foreign body appearance within the pelvis

(Fig. 1A). Excretory urography revealed that it was in the bladder (Fig. 1B), and ultrasonography confirmed an irregular shaped, 3x4 cm stone in the bladder. At cystoscopic examination, stone formation with projected wire pieces was observed. The foreign body was removed by open surgical approach and found to comprise of a piece of copper wire (2 mm in diameter) (Fig. 2).

DISCUSSION

The bladder can be the site of various types of foreign bodies. Surprising foreign bodies such as light bulbs, plastic beans, blu-tacks and thermometers have been reported (1-4). We report a plastic-coated copper wire which formed a nidus for stone formation in the bladder. The case illustrates that patients who suffer from recurrent urinary tract infections should be evaluated with care. Although rare, the possibility of a foreign body, which could be detected simply by abdominal x-ray, should be recognised especially in patients with mental disorders. The treatment of foreign bodies in the bladder are usually via the endoscopic route. However, foreign bodies can

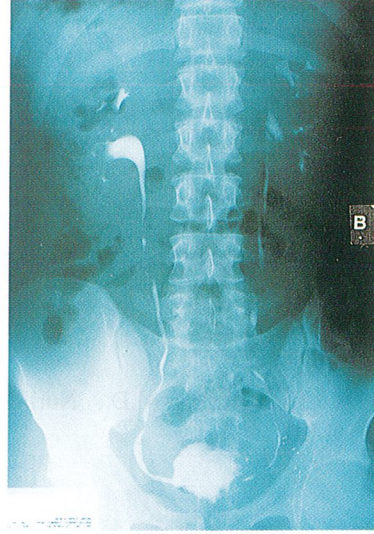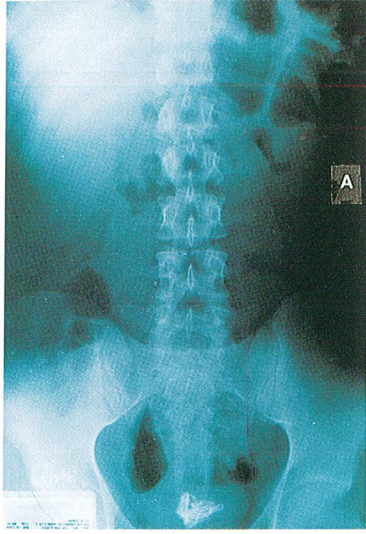


Fig - 1 : Appearance of copper wire on abdominal x-ray (A) and excretory urography (B).

Correspondence to : Dr. Bora KÜPELİ
Beyazgül sitesi A - 1 / 21
Ümitköy
06530 ANKARA - TURKEY
Phone : 312 - 214 10 00 / 6232
Fax : 312 - 212 90 21

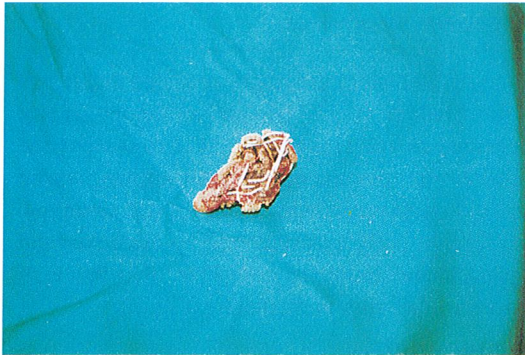


Fig - 2 : Surgically removed foreign body with stone formation.

provide a nidus for stone formation, and it is difficult to fragment large stones around the foreign body. On the other hand, there is the possibility of urethral injury due to extraction of a rigid foreign body, as in our case, and we think that open surgery is more suitable in these cases.

REFERENCES

1. Wenderoth U, Jonas U : Masturbation injuries. Eur Urol 1980; 6 : 312-313.
2. Abdulla MM: Foreign body in the bladder. Br J Urol 1990; 65 : 420-421.
3. Eckford SD, Persad RA, Brewster SF, Gingell JC : Intravesical foreign bodies: Five- year review Br J Urol 1992; 69 : 41-45.
4. Kelly SB, Young MR : Blu-tack in the bladder. Br J Urol 1988; 61 : 94-95.