

CASE REPORTS

EXTENSIVE AORTIC CALCIFICATION: A SURGICAL CHALLENGE

Belhan AKPINAR, M.D., Mert YILMAZ, M.D., Hugo VANERMAN*, M.D., Ralph De GEEST*, M.D.

Florence Nightingale Hospital, Department of Cardiovascular Surgery, İstanbul, Turkey
O.L.V. Hospital, Department of Cardiovascular Surgery*, Aalst, Belgium
Gazi Medical Journal 1998; 9 : 82-85

SUMMARY : Extensive calcification of the aorta can cause serious technical difficulties for the surgeon. We encountered such a problem in a patient who underwent a redo coronary artery bypass grafting (CABG) combined with aortic valve replacement (AVR). The problem was overcome by performing an endarterectomy of the ascending aorta and aortic root replacement with a stentless porcine xenograft (Edwards Prima Stentless Bioprosthesis 2500) combined with CABG. An echocardiographic examination performed ten days after the operation showed a mean systolic gradient of 13 mmHg across the valve, and an angiographic study revealed a competent valve with no left ventricular outflow tract obstruction (LVOT) and functional bypass grafts.

Key Words : Endarterectomy, Aortic Root Replacement, Stentless Porcine Xenograft.

INTRODUCTION

Extensive calcification of the aortic wall is a challenge for the cardiac surgeon; both during and after the operation. In addition to the technical difficulties in initiating cardiopulmonary bypass (CPB) and performing the operation itself, cerebrovascular events caused by embolisation of air, calcium, or debris into the circulation can reach 15 % (1, 2).

In this communication, we would like to discuss a case who was operated for ischemic heart disease 12 years ago. She was planned for a redo CABG and aortic valve replacement; but had to undergo a more extensive reconstruction because of a severe aortic calcification.

CASE REPORT

A 62-year old diabetic patient underwent a redo

CABG operation combined with aortic root replacement. She had received three separate venous grafts during her first operation in 1981, namely to the left anterior descending anterior (LAD), circumflex (Cx), and right coronary artery (RCA). She had angina and history of a pulmonary edema episode. A recent coronary and left ventricular angiography revealed a critical left main stem lesion and an occlusion of the venous bypass to the Cx branch. Although, the graft to the LAD was patent there was some luminal irregularity. The left ventricular angiography revealed an heavily calcified aortic wall and aortic stenosis with a mean systolic gradient of 60 mmHg (BSA=1.83 m²) and also moderately decreased Left ventricular function. The patient was operated on according to these findings.

The sternum was opened with an oscillating saw and the heart was freed of adhesions. While this was

being done, the vein was harvested from the leg simultaneously. Although the initial planning was to implant the left internal mammary artery (LIMA) to the Cx artery, this was not done because there were calcific plaques on the LIMA and its flow was very low.

It was possible to cannulate the ascending aorta near the innominate artery where it was free of calcification. Single two-stage venous cannula was used for venous cannulation; and left atrial venting through the right superior pulmonary vein was used for decompression of the heart. Myocardial protection was achieved by moderate hypothermia, topical cooling, and retrograde cold crystalloid cardioplegia. After the aorta was cross-clamped and cardioplegia was running, a vertical aortotomy towards the non-coronary cusp was performed. The aorta was extensively calcified, starting from the LVOT up to 4 cm above the valve. The valve was resected, and decalcification of the LVOT and endarterectomy of the aortic wall were performed. After this, a 19-mm Edwards Prima Stentless Valve M 2500 was implanted as a whole root with 19 single 4/0 prolene stitches placed on the LVOT.

Before implantation, the dorsal opening of the valve, that was made to correspond to one of the coronary ostia, was closed with a pericardial patch using 6/0 prolene (Fig.1). Since the left and right coronary ostia had been occluded during the endarterectomy, they were not reimplanted. The distal anastomosis was performed with 4/0 prolene continuous suture technique between the porcine root

and the aorta near the arcus.

The posterior wall of the anastomosis was strengthened with teflon felt. After that, the coronary anastomosis were performed. First, an end-to-side anastomosis was performed using a segment of vein with the obtuse marginal (OM) branch of the Cx artery using 7/0 prolene. Using the same vein, a side-to-side anastomosis was performed with the previous vein going to the LAD distal to the narrowing. Since the previous by-pass to the RCA was open, it was not replaced. However, since it was not long enough to reach the neo-aorta, a new piece of vein was anastomosed to this vein in an end-to-end fashion. The proximal end of this vein was implanted to the opening on the anterior side of the porcine art using 7/0 prolene. Finally, the vein coming from the left system was anastomosed to the new vein end-to-side, using 7/0 prolene continuous suture (Fig. 2). The patient was weaned from CPB with high doses of inotropes. An intra-aortic balloon pump (IABP) had to be installed in the early postoperative period because of low cardiac output. She was extubated in 24 h and the IABP was removed in 48 h. CPB time was 230 min, while the ischemic time was 165 min.

The transthoracic (2 Dimensional, M-Mode and Doppler) echocardiographic examination 10 days postoperatively revealed a competent aortic valve with a mean gradient of 13 mmHg. The effective-orifice area (EOA) was 1.6 cm². This was

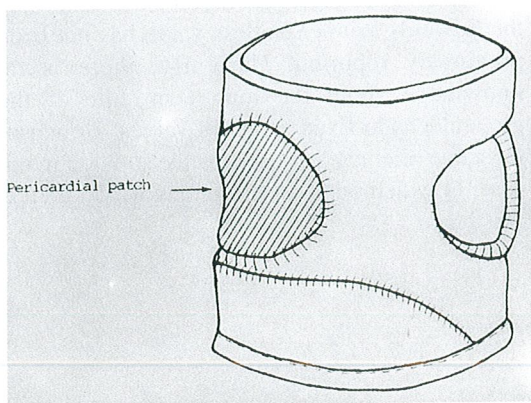


Fig - 1 : One of the openings in the valve corresponding to the coronary ostia is closed with a pericardial patch.

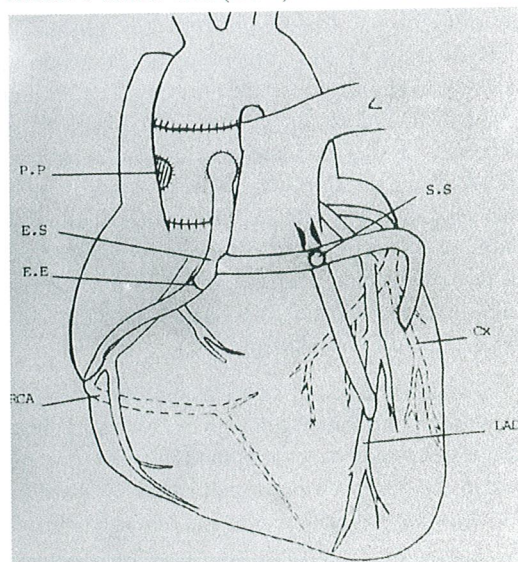


Fig - 2 : This figure shows the new coronary artery anastomosis. Cx: Circumflex coronary artery; EE: End-to-end anastomosis; ES: End-to-side anastomosis; LAD: Left anterior descending artery; PP: Pericardial patch; SS: Side-to-side anastomosis; RCA: Right coronary artery.

measured using the continuous equation after calculation of the left ventricular outflow tract area. Angiographic examination performed before discharge showed again a competent aortic valve with functional by-pass grafts and no LVOT obstruction (Fig.3).

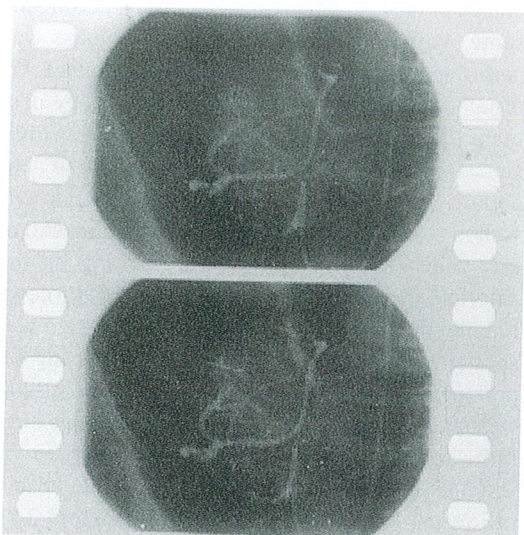


Fig - 3 : Coronary angiographic examination showing functional vein grafts.

DISCUSSION

The overall mortality for AVR combined with CABG is about 5-8% (3, 4). The risk and technical difficulties are even more in combined reoperations. Furthermore, an extensive calcification of the ascending aorta poses an additional challenge for the surgeon. The optimal surgical technique under these circumstances is debatable. Using a composite graft and implanting the proximal anastomosis on the prosthesis can be one solution. However, in cases with a small aortic annulus and large body surface areas (BSA), such as ours, a 19-mm mechanical prosthesis can give high gradients causing afterload mismatches and poor clinical improvement (5, 6).

The advantages of stentless porcine xenograft in small annuli have been well documented. Their major advantage is better hemodynamic properties due to the absence of artificial stents which allow for an increased orifice area and less gradients (5, 7). The Edwards Prima Stentless valve can be implanted in subcoronary position after scalloping the whole ring, as a mini-root or entire root replacement (7). Since the aorta had been endarterectomised in our case, an entire root

replacement had to be performed. The porcine aortic wall of the Prima valve was a fine tissue to work on while performing the distal anastomoses with the native aortic wall, and there was minimal blood loss since there was no oozing from the porcine graft.

The long cross-clamp time for the procedure requires optimal myocardial protection. This was achieved with hypothermia at 25°C, topical cooling with sludge ice, and retrograde crystalloid cardioplegia. Some centers have reported encouraging one-year results with stentless valves both with the subcoronary implantation or the inclusion cylinder techniques and the total root replacement technique (4, 8). Late hemodynamic function was comparable to an aortic homograft (9). Most reports show acceptable mortality rates and lower transvalvular gradients, especially in smaller sizes (10). The Edwards Prima Stentless aortic valve is an aortic root cylinder which can be used for subcoronary implantation, as an inclusion cylinder or as a complete as in our case (11).

The versatility of the Edwards Prima Stentless aortic valve has some advantages in complex and unexpected conditions. Although early hemodynamic data are good, further follow-up will be necessary to evaluate calcification ratio and progress of aortic insufficiency to assess the real benefit of this new generation bioprosthetic valve. Some groups have reported only the use of endarterectomy of the ascending aorta to facilitate aortic valve replacement (12). Although endarterectomy alone leaves the other adventitia intact, the risk of bleeding remains high and the risk of aortic dissection occurring after the endarterectomy is unknown (12).

To our knowledge, total root replacement using the Edwards Prima Stentless valve has not been previously reported. Currently, there is no knowledge about the long term fate of the glutaraldehyde fixed stentless valves. However, the valve offered a very acceptable solution in our case, in which other constructions would be less feasible.

Correspondence to : Dr.Belhan AKPINAR
Florence Nightingale Hastanesi
Kardiyovasküler Cerrahi Bölümü
Şişli
80220 İSTANBUL - TÜRKİYE
Phone : 212 - 224 49 50 / 4173
Fax : 212 - 224 49 82

REFERENCES

1. Razi DM : The challenge of calcific aortitis. *J Card Surg* 1993; 8 : 102-107.
2. Peigh PS, Di Sese VJ, Collins JJ, Cohn LH : Coronary bypass grafting with total calcified or acutely dissected aorta. *Ann Thorac Surg* 1991; 51 : 102-105.
3. Lytle BW, Cosgrove DM III : Coronary artery bypass surgery. *Curr Probl Surg*. 1992; 29 : 733-807.
4. Sidiropoulos A, Hotz H, Tschesnow J, Konertz W : Stentless porcine bioprosthesis for all types of aortic root pathology. *Eur J Cardiothorac Surg* 1997; 11 : 917-921.
5. Barratt- Boyes BG, Christie GW, Randkiwi PJ: The stentless bioprosthesis: surgical challenges and implications for long term durability. *Eur J Cardiothorac Surg* 1992; 6 (Suppl 1) : 39-44.
6. Westaby S, Parry A, Pillai R : Aortic root replacement: modifications of technique with improvements in technology. *Eur J Cardiothorac Surg* 1992; 6 (Suppl 1) : 44-50.
7. Konertz W, Wyand M, Sidiropoulos A, Schwammenthal E, Breithardt G, Scheld HH : Technique of aortic valve replacement with the Edwards Stentless Aortic Bioprosthesis 2500. *Eur J Cardiothorac Surg* 1992; 6 : 274-277.
8. Dossche K, Vanermen H, Deanen W, Pillai R, Konertz W : Hemodynamic performance of the Prima Edwards Stentless aortic xenograft: early results of a multicenter clinical trial. *Thorac Cardiovasc Surg* 1996; 44 : 11-14.
9. Westaby S, Amarasena N, Long V, Prothero A, Amarasena GA, Banning AP, Pillai R, Omerad O : Time related hemodynamic changes after aortic replacement with the freestyle stentless xenograft. *Ann Thorac Surg* 1995; 60 : 1633-1638.
10. Van Nooten GJ, Caes F, Francois K, Van Belleghem Y : Toronto stentless aortic valve replacement in elderly patients. *S Afr Med J* 1996; 86 (Suppl 2) : 69-73.
11. Dossche K, Venermen H : Experience with the Edwards Prima Stentless aortic bioprosthesis: a 2 year review. *J Heart Valve Dis.* 1995; 4 (Suppl 1) : 85-88.
12. Gantijo BF, Vrandecic M, Fantini FA, Oliveira MH, Avelar SO : Porcine stentless aortic valve in re-replacements and acute aortic valve endocarditis. *J Heart Valve Dis.* 1995; 4 : 171-175.