

LETTERS

THE ASSOCIATION OF BILATERAL PLANTAR PSORIASIS AND GEOGRAPHIC TONGUE

Psoriasis is a chronic and relapsing skin disorder, which may present in different clinical patterns (1). Geographic tongue (GT) is characterised by whitish borders and flat erythematous areas devoid of filiform papillae (2). In some reports, the association of GT, pustular psoriasis, psoriasis and atopic dermatitis have been examined (2, 3).

We found a 52-year-old female patient suffering from relapsing eczema-like lesions on her right plantar region for 20 years. She had no family history of GT. Physical examination was normal. Dermatological examination revealed diffuse, sharp bordered, erythematous plaque like lesion with scales on right plantar region (Fig. 1) together with pitting and subungual keratosis of toe nails. A typical GT was present (Fig. 2). There were no laboratory abnormalities. The histopathologic

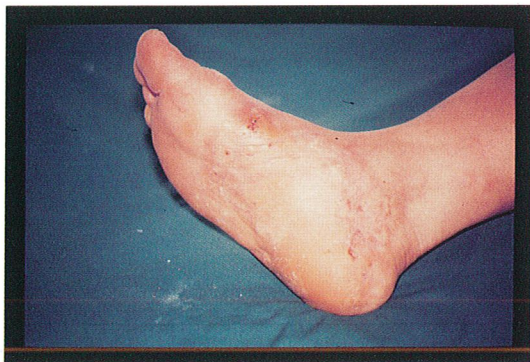


Fig - 1 : A well-defined plaque-like psoriatic lesion on right plantar region.

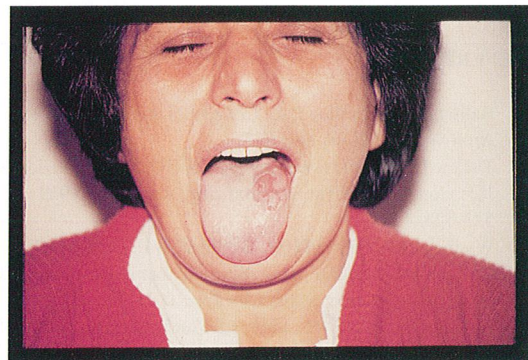


Fig - 2 : Geographic tongue.

examination of the scaling lesions was diagnostic of psoriasis (Fig. 3).

Oral mucosa involvement is quite rare in psoriasis (4). GT is a benign process that can be diagnosed clinically. Hereditary forms are uncommon (2). There are very few reports about the association of GT, psoriasis and atopic dermatitis. On the other hand, this condition is controversial. Is it the mucosal finding of psoriasis or a different clinical entity? There is a report of GT with histopathologically confirmed pustular psoriasis (5). Erdi et al. examined 88 psoriatic patients for the presence of oral lesions. In their study, GT was present in 5.68 % of the patients (6). Our case had bilateral plantar psoriasis and relapsing GT from time to time.

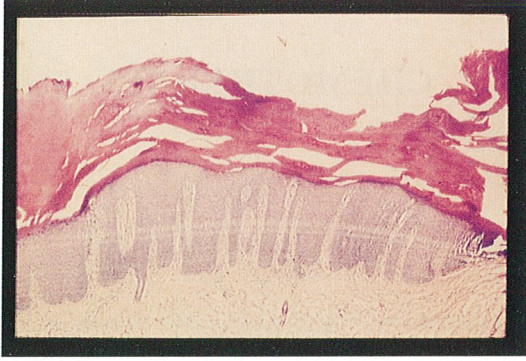

Fig - 3 : Typical histopathological appearance for psoriasis.

A.Burhan AKSAKAL, M.D.,

Nilsel İLTER, M.D.,

Murat Orhan ÖZTAŞ, M.D.,

M.Ali GÜRER, M.D.,

Gazi University, Faculty of Medicine,

Department of Dermatology,

Ankara, Turkey

REFERENCES

1. Fitzpatrick TB, Eisen AZ, Wolff K, Freedberg IM, Austen KF : Dermatology in General Medicine.Fourth Ed. New York : Mc Graw-Hill Book Company, 1993; 489-514.
2. Kuramoto Y, Tadaki T, Hatchome N, Tagami H : Geographic tongue in two siblings. Dermatologica 1987; 174 : 298-302.
3. Hubler WR Jr : Lingual lesions of generalized pustular psoriasis. Report of five cases and a review of the literature. J Am Acad Dermatol 1984; 11 : 1069-1076.
4. Zunt SL, Tomich CE : Erythema Migrans- a psoriasiform lesion of the oral mucosa. J Dermatol Surg Oncol 1989; 15 : 1067-1070.
5. Kanerva L, Hietanen J : Ultrastructure of oral mucous membrane lesions in psoriasis. Acta Derm-Venereol (Stockh) 1984; 64 : 191-196.
6. Erdi H, Kundakçı N, Taşpınar R, Taşpınar A : Oral mucosa involvement in psoriasis. Tıp ve Sağlık Dergisi 1997; 1 : 14-20.