

GLIAL FIBRILLARY ACIDIC PROTEIN IMMUNOREACTIVITY IN UTERINE ENDOMETRIAL ADENOCARCINOMAS

Kutsal YÖRÜKOĞLU, M.D., Safiye AKTAŞ, M.D., Gonca ATAÇ, M.D., Emek ÖZEN, M.D.

Dokuz Eylül University, Faculty of Medicine, Department of Pathology, İzmir, Turkey
Gazi Medical Journal 1997; 8 : 148-150

SUMMARY :

Purpose : Glial fibrillary acidic protein (GFAP) is the major protein constituent of glial filaments and expressed in both central and peripheral nervous systems and outside of these systems and Müllerian origin neoplastic cells, as well. Twenty-two uterine endometrial adenocarcinomas selected from archival files that have follow-up information were stained for GFAP, immunohistochemically. **Methods :** The surgical and pathologic reports, follow-up files and the tumor tissue sections were examined. **Results :** Patients' age ranged from 41 to 67 years and follow-up period from 6 to 31 months. Two cases were dead at 6th and 24th months. In two cases, vaginal recurrence was noted. The other cases were alive and without disease at the last follow-up. Twelve, 3, 4, and 3 cases were FIGO Stage I, II, III and IV, respectively. GFAP expression was observed in 15 (68%) cases. No correlation between GFAP expression and stage was observed by Spearman Correlation Test. **Conclusion :** These results suggest that GFAP expression may be valuable in the differential diagnosis of metastatic carcinomas favouring Müllerian duct-originated neoplasms. The case number and follow-up period times are low; however GFAP expression is supposed not to be related to prognosis. This unrelationship may support the hypothesis that GFAP expression is the result of multipotential differentiation of cells of the Müllerian duct lineage.

Key Words: Glial Fibrillary Acidic Protein, Immunohistochemistry, Endometrial Carcinoma.

INTRODUCTION

Glial Fibrillary Acidic Protein (GFAP) is the major protein constituent of glial filaments expressed in astrocytes, developing oligodendroglia, and ependymal cells, interstitial cells of the pineal gland, and neurohypophysis cells (1-3). This expression is retained in these cells after neoplastic transformation and has been used to diagnose central nervous system (CNS) tumors (4). Outside the CNS, GFAP has been localised in various cells of the peripheral nervous system (5), and in cells not associated with the nervous system

such as cartilages (1, 2), malignant pleomorphic adenomas, meningiomas, renal cell carcinoma metastasis (6) , normal, hyperplastic, and neoplastic breast cells (7), lens epithelium (8), perisinusoidal stellate cells of the liver (9), and Müllerian origin neoplastic cells (10,11).

The detection of GFAP in a metastatic carcinoma was suggested to be a potential criterion to warrant consideration of a Müllerian neoplasia (11). GFAP expression is not strictly specific for Müllerian origin neoplasia and may be encountered in renal cell carcinomas (6) or breast carcinomas

(7), as well.

We studied 22 uterine endometrioid adenocarcinoma cases to analyse the prognostic importance of this expression.

MATERIALS AND METHODS

Twenty-two cases on clinical follow-up were selected from 46 endometrial carcinoma cases diagnosed at Dokuz Eylül University, Medical Faculty. The surgical and pathologic reports, follow-up files, and hematoxylin and eosin-stained sections were examined. In addition, immunohistochemical staining was performed using the avidin-biotin-peroxidase complex (ABC) technique (12) with the primary antibody (GFAP-prediluted; YLEM, Italy) on a section from a representative paraffin block obtained from the hysterectomy specimens. Negative control sections were represented by tissue stained by substitution of non-immune rabbit serum or mouse ascite's fluid for primary anti-sera. Sections of unrelated tumors or normal tissues, known to contain the determinants that were assessed, served as positive controls.

Data were analysed using SPSS for Windows (release 5.0.1; Microsoft Corporation, Redmond, WA). Comparisons were performed using the Spearman Correlation Test for non-parametric data. Results with $p < 0.05$ or $-1 < r > 1$ were considered significant.

RESULTS

Patients' ages ranged from 41 to 67 years (mean, 52 years). Follow-up period ranged from 6 to 31 months (mean 17.7 months). Two cases died at 6th and 24th months. In two cases, vaginal recurrence was noted. The other 18 cases were alive and well with no evidence of disease at the last follow-up. Twelve cases were FIGO stage I (1, Ia; 8, Ib; 3, IC), 3 cases were FIGO stage II (3, IIb), 4 cases were FIGO stage III (2, IIIa; 2, IIIb), and 3 cases were FIGO stage IV (2, IVa; 1, IVb). Nineteen cases were endometrioid adenocarcinomas, 2 were clear cell carcinomas and 1 was serous carcinoma. Twelve of the 19 endometrioid adenocarcinoma cases were grade I, 4 were grade II, and 3 were grade III.

Immunohistochemical staining revealed GFAP expression in 15 cases (68%), (Fig. 1). No staining was obtained in 7 cases. In the positive cases,

staining was observed in the cytoplasm of most of the tumor cells and the intensity was strong. GFAP immunoreactivity correlated with the stage, grade, and histologic type of the cases by Spearman Correlation Test and no correlation was found ($p=0.221$, $r=0.3032$).

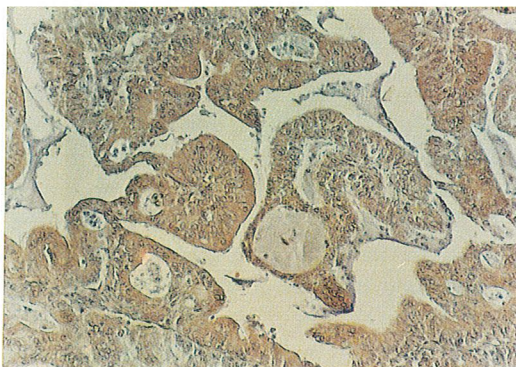


Fig - 1 : Diffuse GFAP expression in uterine endometrial adenocarcinoma x10.

DISCUSSION

Glial Fibrillary Acidic Protein (GFAP) is expressed outside the central and peripheral nervous system as in cartilage (1, 2), salivary gland tumors, meningiomas, renal cell carcinoma metastases (6), lens epithelium (8), breast epithelium (7), and hepatic Kupffer cells (9). Recently, strong immunoreactivity for GFAP was reported in malignant mixed Müllerian tumors and endometrial and ovarian adenocarcinomas, both of which are derived from Müllerian epithelium (10, 11).

These unexpected immunoreactivities suggest authentic GFAP production. Some epitopes of other intermediate filament proteins may become modified during routine tissue processing in such a way that they may give GFAP-like immunoreactivity, and this problem was stated to be resolved by immunoblotting experiments (6). Two-dimensional gel electrophoresis and immunoblotting studies revealed unequivocal GFAP expression (11).

As the GFAP expression seems to be a rare event in nonmüllerian carcinomas (6), detection of

GFAP even focally in a metastatic carcinoma was suggested to be a valuable aid in differential diagnosis (11). Our results revealed positive staining in more than half of the cases (68 %) and the staining was usually diffuse and intense. As the GFAP expression is not strictly specific for Müllerian duct origin neoplasias, one should be aware of the fact that GFAP expression also may reflect a renal cell carcinoma or breast carcinoma (6, 7).

The biologic significance of the expression of GFAP remains obscure. Phenotypic divergency, heterogeneity of GFAP polipeptides, oncogenic relationship with Müllerian duct cells, or the neometaplasia of the Müllerian duct cells were suggested (13). In both epithelial and non-epithelial Müllerian duct-type tumors, it may reflect the multipotential differentiation capacity of cells of the Müllerian duct lineage (11). We have not observed significant difference between GFAP expression and the stage, grade, histologic type, or prognosis. The number of our cases and follow-up period times are low, but one may suggest that GFAP expression is not related to prognosis. As neoplasia is a multistep procedure, the lack of association of prognosis with GFAP expression supports the hypothesis of multipotential differentiation of cells of the Müllerian duct lineage.

Neuroendocrine differentiation is well known in Müllerian neoplasms (14). S-100 protein expression in endometrioid adenocarcinomas was observed in 78% of the cases (15,16). The case number and follow-up period times are low, however GFAP expression is supposed not to be related to prognosis, but this fact may support the hypothesis that GFAP expression is the result of multipotential differentiation of cells of the Müllerian duct lineage.

Correspondence to : Dr.Kutsal YÖRÜKOĞLU
Dokuz Eylül Üniversitesi Tıp Fakültesi
Patoloji Anabilim Dalı
İnciraltı
35340 İZMİR - TÜRKİYE
Phone : 232 - 259 59 59 / 3410
Fax : 232 - 259 05 41

REFERENCES

1. Notohara K, Hsueh CL, Awai M : Glial fibrillary acidic protein immunoreactivity of chondrocytes in immature and mature teratomas. *Acta Pathol Jpn* 1990; 40 : 335-342.
2. Viale G, Doglioni C, Dell'orto P, Zanetti G, Iuzzolino P, Bontempini L, Coggi G : Glial fibrillary acidic protein immunoreactivity in human respiratory tract cartilages and pulmonary chondromatous hamartomas. *Am J Pathol* 1988; 133 : 363-373.
3. Miettinen M, Clark R, Virtanen I : Intermediate filament proteins in choroid plexus and ependyma and their tumors. *Am J Pathol* 1986; 123 : 231-240.
4. Velasco ME, Dahl D, Roessmann U, Gambetti P : Immunohistochemical localization of glial fibrillary acidic protein in human glial neoplasms. *Cancer* 1980; 45 : 484-494.
5. Kawahara E, Oda Y, Ooi A : C.Expression of glial fibrillary acidic protein (GFAP) in peripheral nerve sheath tumors. A comparative study of immunoreactivity of GFAP, vimentin, S-100 protein, and neurofilament in 38 schwannomas and 18 neurofibromas. *Am J Surg Pathol* 1988; 12 : 115-120.
6. Budka H : Non-glial specificities of immunohistochemistry for the glial fibrillary acidic protein (GFAP). *Acta Neuropathol (Berl)* 1986; 72 : 43-54.
7. Gould VE, Koukoulis GK, Jansson DS, Nagle RB, Franke WW, Moll R : Coexpression patterns of vimentin and glial filament protein with cytokeratins in the normal, hyperplastic and neoplastic breast. *Am J Pathol* 1990; 137 : 1143-1155.
8. Hatfield JS, Skoff RP, Maisel H, Eng LF : Glial fibrillary acidic protein is localised in the lens epithelium. *J Cell Biol* 1984; 98 : 1895-1898.
9. Gard AL, White FP, Dutton GR : Extra-neural glial fibrillary acidic protein (GFAP) immunoreactivity in perisinusoidal stellate cells of rat liver. *J Neuroimmunol* 1985; 8 : 359-375.
10. Liao SY, Choi BH : Expression of glial fibrillary acidic protein by neoplastic cells of Müllerian origin. *Virchows Arch Cell Pathol* 1986; 52 : 185-193.
11. Moll R, Pitz S, Levy R, Weikel W, Franke WW, Czernobilsky B : Complexity of expression of intermediate filament proteins, including glial fibrillary acidic protein, in endometrial and ovarian adenocarcinomas. *Hum Pathol* 1991; 22 : 989-1001.
12. Hsu S, Raine L, Fanger H : Use of avidin-biotin-peroxidase complex (ABC) in immunoperoxidase techniques: A comparison between ABC and unlabeled antibody (PAP) procedures. *J Histochem Cytochem* 1981; 29 : 577-580.
13. Young RH, Kleinman GM, Scully RS : Glioma of the uterus. Report of a case with comments on histogenesis. *Am J Surg Pathol* 1981; 5 : 695-699.
14. Manivel C, Wick MR, Sibley RK : Neuroendocrine differentiation in müllerian neoplasms. *Am J Clin Pathol* 1986; 86 : 438-443.
15. Herrera GA, Turbat-Herrera EA, Lott RL : S-100 protein expression by primary and metastatic adenocarcinomas. *Am J Clin Pathol* 1988; 89 : 168-176.
16. Kahn HJ, Marks A, Thom H, Baumal R : Role of antibody to S-100 protein in diagnostic pathology. *Am J Clin Pathol* 1983; 79 : 341-347.