

CASE REPORTS

ADULT WILMS' TUMOR : A REPORT OF TWO CASES

Müge AKMANSU, M.D., Tijen YAPICI*, M.D., Tülay EVRENKAYA**, M.D.

Gazi University, Faculty of Medicine, Department of Radiation Oncology, Ankara, Turkey
Ankara Oncology Hospital, Department of Radiation Oncology*, Ankara, Turkey
Sevgi Hospital, Department of Pathology**, Ankara, Turkey
Gazi Medical Journal 1997; 8 : 156-158

SUMMARY :

Adult Wilms' tumor, unlike that seen in childhood, is a rare disease. We are reporting two cases, one of which is alive with no evidence of disease at her 65th month of follow-up and the other with no evidence of disease at her tenth month after which she was lost to follow-up. The literature has been reviewed and the prognosis and treatment alternatives are presented.

Key Words: Adult Wilms' Tumor, Radiotherapy.

INTRODUCTION

Wilms' Tumor is a common tumor among childhood tumors. Although survival varies according to prognostic factors, 80 % of patients who suffer from Wilms' tumor are cured with combined treatment (1). It is difficult to state the exact incidence of this tumor in adults due to incomplete and conflicting data, but it varies between 4.4 to 11.1 percent of all Wilms' tumours (2).

In this paper ,we report two adult patients with nephroblastoma. Both of them were staged according to the classification of the National Wilms' Tumor Study Group.

CASE REPORTS

Case 1: An 18-year-old female patient came with the complaint of left flank pain in November 1991. On physical examination, a 9X8 cm mass was palpated at the region of the left kidney. In the computerized tomography of the patient, a mass of

renal origin with approximately 10X9X8 cm dimensions was detected. On urine examination, microscopic hematuria was observed. With these findings, left nephrectomy was performed in November 1991. The histopathological diagnosis was Wilms' tumor and there was residual disease. With these findings, the patient was accepted as stage III (according to NWTS staging system). Postoperative radiotherapy was administered at doses of 200 cGy per fraction and 5 fractions/week with a total dose of 2000 cGy. This dose was applied to the tumor bed and paraaortic region from opposite parallel sides. After radiotherapy, she received three courses of DAVE chemotherapy (Actinomycine-D: 0.6mg/m², on the first and eighth days; Doxorubicine : 30mg/m², first and eighth days; Vincristine : 0.8mg/m², first and eighth days; Cyclophosphamide : 200mg/m², first and eighth days). She had no evidence of disease on her tenth month after which she was lost for follow-up (Fig. 1).

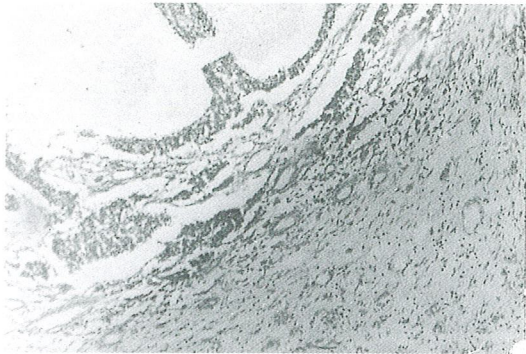


Fig - 1 : Tubule-like formations made up of atypical epitheloid cells in the tumor tissue are seen among the stroma composed of cells in the form of spindle-like fibroblasts (H.E.X100).

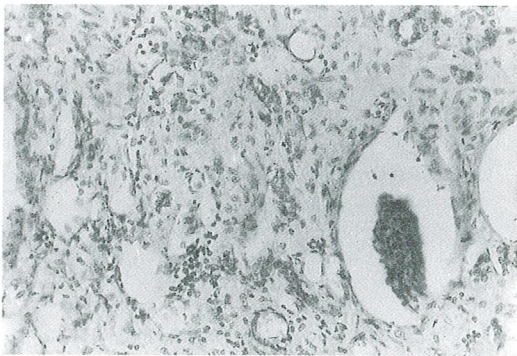


Fig - 2 : Mesenchymal stromal component and glomeruloid are seen within the tumor tissue (H.E.X100).

Case 2 : A 21-year-old female patient who complained of left flank pain came for medical examination in September 1991. A mass was palpated at the left kidney region on physical examination. Since a 7X6 cm mass was seen on ultrasonography originating from the kidney and since there was macroscopic hematuria on urinary examination, she underwent left nephrectomy in September 1991. The patient was accepted as stage II (according to NWTS) . Since it was known that the prognosis was worse in adults and since it was not possible to determine the histopathologic subgroup, a total of 2000 cGy radiotherapy with

200 cGy/fraction daily doses was administered postoperatively to the tumor bed and paraaortic region from opposite parallel fields. The patient did not receive any chemotherapy following radiation therapy and is alive with no evidence of disease at her 65th month of follow-up (Fig. 2).

DISCUSSION

The first case of Wilms' tumor in an adult was reported by Kocker and Langhans in 1878.

The preoperative diagnosis of Wilms' tumor is extremely difficult in an adult patient (3, 4). In Esersky's series of 56 cases, none were diagnosed correctly before surgery (5). In fact, a preoperative diagnosis of Wilms' tumor is difficult to in adults, because diagnostic imaging techniques such as ultrasonography, intravenous pyelography (IVP), angiography, computerized tomographic scanning (CT scan), or magnetic resonance imaging only demonstrates a renal mass. Sometimes, Wilms' tumor is confused with renal cell carcinoma. Nevertheless, there is no histopathological difference between the adult Wilms' tumor and the pediatric Wilms' tumor (6, 7).

The most common complaints seen in order of frequency are flank pain (66 %), mass (48 %), and haematuria (36 %) (7). Diagnostic, angiography, computerized tomography, and IVP should be performed. Angiography shows a hypovascular mass (6, 8). IVP is useful for the localization of the lesion, but it is not a suitable diagnostic technique in children (6, 5). The tumor is seen as a nonhomogenous intrarenal mass in computerized tomographic imaging. CT is beneficial in delineating the secondary invasion of the big vessels and the existence of the tumor itself (4). In children, large tumor size, distant metastasis, and lymph node involvement suggest a poor prognosis. The first National Wilms' Tumor Study (NTSW-1) identified a small subset (11 %) of patients with anaplastic, rhabdoid, or sarcomatous features and referred to these features as having "unfavourable histology" while the remaining monomorphous epithelial tumors were referred to as having a "favourable histology" (6). There is not any other similar classification which is based on the histopathologic findings in adult Wilms' tumors.

Surgical treatment is important in the treatment of adult Wilms' tumor, as well as in childhood Wilms' tumor. Surgery may be the first step for a

curative possibility and has a role in its diagnosis. Radiotherapy and chemotherapy have limited effects without surgical treatment, and it is known that this type of treatment is not effective as it is in childhood Wilms' tumor (1, 9).

Essentially, any single treatment modality seems to be unsatisfactory to eradicate Wilms' tumor in adults (10). In adults, surgical treatment is suggested with the highest priority, and after this treatment some authors suggest that radiation therapy should be administered to the tumor bed, followed by a combination chemotherapy consisting of actinomycine-D, vincristine and doxorubicin (6, 11).

As a matter of fact, due to the rarity of this tumor in adults, a definitive treatment plan is undefined.

Chemotherapy protocols successful in childhood Wilms' tumor may be unsatisfactory in adults (1). In recurrent cases, the most effective chemotherapy protocols consist of cisplatin-based regimens (1, 12).

Lymph node invasion and a tendency for haemategenous metastasis are also seen in adults as it is in the paediatric age group (4). The most frequent places of metastasis are, in order of frequency, the lungs, liver, bones, skin, bladder, colon, brain, and contralateral kidney (6). However, the natural course and prognosis are different in the two groups. In adults, the response to treatment is worse than in the paediatric age group (6). Metastasis rate is 29% in adults, while in the paediatric age group this rate is approximately 10% (1). The prognosis is worse in adults than in paediatric patients (6, 7, 12, 13). However, the results of treatment published more recently for adult patients classified as having stage I or II disease are promising. The outcome of treatment is similar to that seen in children (14, 15).

Because of the rarity of this disease, the treatment of these tumors in adults is not well established. We believe they may be staged in the same way as in children according to the guidelines of the National Wilms' Tumor Study Group. In our opinion, the therapeutic approach should be like the treatment plan applied to unfavourable paediatric Wilms' tumors.

Correspondence to : Dr.Müge AKMANSU
Şair Nedim Sok. No : 21/8
Aşağı Ayrancı
06690 ANKARA - TÜRKİYE
Phone : 312 - 438 83 29
Fax : 312 - 222 96 98

REFERENCES

1. Abratt RP, Preez MD, Kaschula R : Adult Wilms' tumor: Cisplatin and etoposide for relapse after adjuvant chemotherapy. *Cancer* 1990; 65 : 890-892.
2. Denes FT, Nahas WC, Alfer V : Adult Wilms' tumor: treatment with surgery, radiotherapy and chemotherapy. *Urology* 1982; 9 : 187-189.
3. Dawson NA, Klein MA, Taylor GH : Salvage therapy in metastatic adult Wilms' tumor. *Cancer* 1988; 62 : 1017-1021.
4. Babaian RJ, Skinner DG, Waisman J : Wilms' tumor in the adult patient. *Cancer* 1980; 45 : 1713-1719.
5. Esersky GL, Saffer SH, Panoff LE, Jacop M : Wilms' tumor in the adult: review of the literature and report of three additional cases. *J Urology* 1947; 58 : 397-411.
6. Kumar A, Lal B, Singh M, Kapur B : Adult Wilms' tumor:report of a case and review of the literature. *Jap J Surg* 1990; 20 : 585-589.
7. Kilton L, Matthews MJ, Cohen MH : Adult Wilms' tumor:a report of prolonged survival and review of literature. *J Urology* 1980; 124 : 1-5.
8. Merten DF, Yang SS, Bernstein J : Wilms' tumor in adolescence. *Cancer* 1976; 3 : 1532-1538.
9. Bard HR, Greenwald ES, Kalnicki S, Sablay BL : Adult Wilms' tumor treated with radiotherapy and chemotherapy : a case report. *J Urology* 1979; 127 : 679-680.
10. Hagiwara M, Tachibana M, Jitsukawas M, Murai M, Nakazon M, Hata M, Tazaki H : Multimodal treatment of advanced adult Wilms' tumor. *J Urology* 1982;127: 535-538.
11. Byrd RL, Evans AE, D'Angio GJ : Adult Wilms' tumor : effect of combined therapy on survival. *J Urology* 1982; 127: 648-651.
12. Sparano JA, Beckwith JB, Mitsudo S, Wiernik PH : Complete remission in refractory anaplastic adult Wilms' tumor treated with cisplatin and etoposide. *Cancer* 1991; 67 : 956-959.
13. Zorlu AF, Atahan IL, Gedikoğlu G, Akyol FH, Gürkaynak M : Erişkin çağ Wilms' tümörü (abs. in English) *Turkish Journal of Oncology* 1994; 9 : 1525-1528.
14. Winter P, Vahlensieck JRW, Miersch WDE, Vogel J, Gokel JM, Hellerich U : Wilms' tumour in adults:review of 10 cases. *Int Urol Nephrol* 1996; 28 : 469-475.
15. D'Angio GJ, Evans A, Breslow N, Beckwith B, Bishop H, Farewell V, Goodwin W, Leape L, Palmer N, Sinks L, Sutov W, Tefft M, Wolff J : The treatment of Wilms' tumor: results of the Second National Wilms' Tumor Study. *Cancer* 1981; 47 : 2302-2311.