

## PSOAS ABSCESS WITH SPONTANEOUS VAGINAL DRAINAGE

Hasan BİRİ, M.D., Zafer SINIK, M.D., Doğan ÜNAL, M.D., İlker ŞEN, M.D.,  
İbrahim BOZKIRLI, M.D.

Gazi University, Faculty of Medicine, Department of Urology, Ankara, Turkey  
Gazi Medical Journal 8 : 195-197, 1997

**SUMMARY:** A 40-year-old woman with a history of diffuse abdominal pain, fever, weight loss, and vomiting was admitted to the hospital, and a painful mass found in the left abdomen. Later with USG and CT scan, the mass was confirmed to be a multiseptate cystic lesion starting from lower pole of the left kidney up to the inguinal region including the psoas major and iliacus muscles. Prulent drainage occurred from the vagina just before the operation. The patient was diagnosed as having a primary psoas abscess with a vaginal fistula and surgical drainage was performed.

**Key Words:** Psoas Abscess, Primary, Vaginal Drainage.

### INTRODUCTION

Psoas abscess was first described in 1881 (1). It is a well-recognized, classical complication of spinal tuberculosis (2). However, with the elimination of tuberculosis, non-tuberculous psoas abscesses are now more commonly observed (3). Non-tuberculous psoas abscesses are generally associated with gastro intestinal lesions (2), perinephric abscess (4), osteomyelitis of the spine, penetrating abdominal wounds, previous surgery (5). In spite of extensive investigation, the etiology cannot be revealed in some others. These are described as idiopathic (2, 3).

A primary pyogenic abscess of the psoas muscle is rare and often is not suspected. Unfamiliarity with the lesion is the major reason for the delay in diagnosis (6). The etiology of a primary pyogenic abscess of the muscle remains speculative. Suppurative lymphadenitis (7, 8) and trauma with formation of a hematoma that becomes infected due to hematogenous seeding (9) have been proposed

as causative factors. A primary pyogenic abscess has a better prognosis and response to drainage than a pyogenic abscess secondary to the other diseases (6).

### CASE REPORT

A 40-year-old woman presented with a 2-month history of diffuse abdominal pain radiating to left hip, fever, weight loss and vomiting. Her medical history revealed a transabdominal hysterectomy 4 years ago. Temperature was 37.8°C, heart rate 98 per minute and blood pressure 110 / 70 mmHg. Physical examination revealed a 25x10 cm painful mass in the left abdomen. Hemoglobin was 8 g/dl, erythrocyte sedimentation rate 75 mm/h and white blood cell count 19600/mm<sup>3</sup>. In intravenous pyelography, obliteration of the psoas shadow, devisualisation of the left kidney and a shadow related to a left abdominal mass were present (Fig. 1). USG and CT showed a multi septate cystic mass starting from lower pole of the left kidney up to the left inguinal

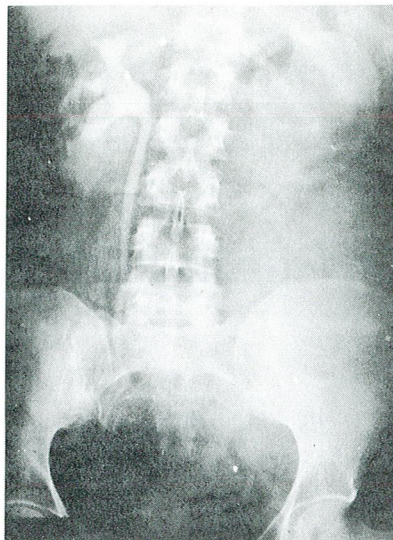


Figure - 1 : Intravenous pyelography. Obliteration of the psoas shadow, devascularisation of the left kidney, and a shadow related to a left abdominal mass.

region including the psoas major and iliacus muscles. Left hidroureteronephrosis was also present and renal parenchyma almost disappeared (Fig. 2 a/b). The abscess fistulized to the vagina before the operation. The abscess was drained with flank exploration and culture taken from the abscess later showed *S. aureus*. Left nephrectomy was performed in the same session. The hydronephrotic kidney was found to be free of infection, but had a very extremely thinned parenchyma. Then the patient received antibiotic therapy and was discharged on the 10th post-operative day.

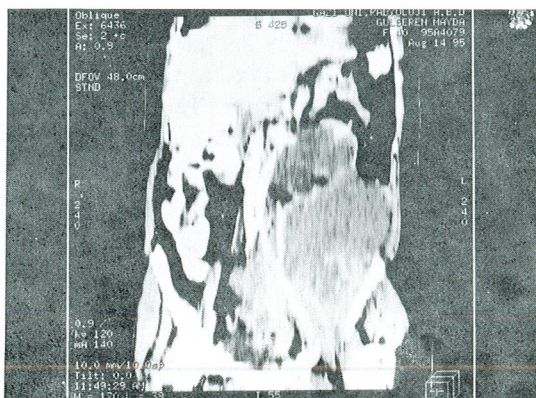

Figure - 2a : Computed tomography of abdomen. A multiseptate cystic mass in the left abdomen, left hidroureteronephrosis.

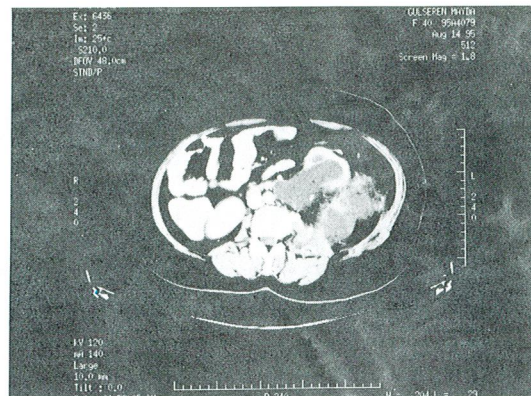


Figure - 2b : Computed tomography of abdomen. A multiseptate cystic mass in the left abdomen, left hidroureteronephrosis.

## DISCUSSION

Abscesses in the retroperitoneum are relatively common infections because of the intimate association of this space with the gastrointestinal tract and axial skeleton. These infections are usually secondary to inflammatory processes in the adjacent structures, but rarely primary infections do occur in this area. The psoas muscle as an integral part of the retroperitoneal space which is involved commonly in infections of this region (9). The psoas abscesses have been reported to have a worldwide incidence of 3.9 cases per year and the most common pathogen is *Staphylococcus aureus* (88.4 % of the cases) (10).

Psoas abscesses commonly present with abdominal or flank pain, flank mass and fever (4, 5). Besides, we observed weight loss and vomiting in our patient. However, the patients may present with nonspecific symptoms as well (4).

The diagnosis of psoas abscess can be established by computerized tomography, ultrasonography, and/or magnetic resonance imaging (2, 5); The main therapy of a psoas abscess is incision and drainage combined with antibiotics (5).

The complications of psoas abscess are pulmonary embolism, hemorrhage, and bowel obstruction. The main cause of death is sepsis (8). In a study of 47 patients, the mortality of psoas abscess has been found to be 13 % (4).

Despite the fact that secondary psoas abscess occurs more commonly, our patient had a primary psoas abscess which is a rare condition. A more important aspect of this case was the spontaneous vaginal drainage which might be due to the transabdominal hysterectomy performed four years ago.

Because of the rarity of primary psoas muscle abscesses, all patients with these infections should be evaluated for predisposing abdominal and pelvic inflammatory processes (9).

Correspondence to : Dr.Hasan BİRİ  
Gazi Üniversitesi Tıp Fakültesi  
Üroloji Anabilim Dalı  
Beşevler  
06500 ANKARA - TÜRKİYE  
Phone : 312 - 214 10 00 / 6233

#### REFERENCES

1. Mynter H : Acute Psoitis. Buffalo Med Surg J 1981; 21 : 202.
2. Williams MP : Non-tuberculous psoas abscess. Clin Radiol 1986; 37 : 253-256.
3. Walsh TR, Reilly JR, Hanley E, Webster M : Changing etiology of iliopsoas abscess. Am J Surg 1992 ; 163 : 413-416.
4. Curtin JJ, Ridley NTF, Colbeck R : Case Report: Staghorn calculus complicated by psoas abscess presenting as flank mass in a teenager. Br J Radiol 1993; 68 : 844-846.
5. Scheepers NJB, Van Bommel PFJ, Bleker OP : Psoas abscess related to spontaneous abortion, intra-uterine contraceptive device and curettage. Acta Obstet Gynecol Scand 1993; 72 : 223-224.
6. Malhotra ByR, Sing KD, Bhan S, Dave PK : Primary Pyogenic Abscess of the Psoas Muscle. J Bone and Joint Surg 1992; 74A : 278-284.
7. Maull KI, Sachatello CR : Retroperitoneal iliac fossa abscess. A complication of suppurative iliac lymphadenitis. Am J Surg 1974; 127 : 270-274.
8. Oliff M, Chuang VP : Retroperitoneal iliac fossa pyogenic abscess. Radiology 1978; 126 : 647-652.
9. Lowe AB, Smith AY : Primary psoas abscess. J Urol 1987; 137 : 485-486.
10. Gruenwald I, Abrahamson J, Cohen O : Psoas abscess : case report and review of the literature. J Urol 1992; 147 : 1624 - 1626.