

# AN ANOMALY OF THE ANTERIOR BELLY OF THE DIGASTRIC MUSCLE

Mehmet ERSOY, M.D., Sabriye DAYI\*, M.D.

Ankara University, Faculty of Health Education, Department of Anatomy, Ankara, Turkey  
Ankara University, Faculty of Medicine, Department of Anatomy\*, Ankara, Turkey  
Gazi Medical Journal 7 : 145-146, 1996

*SUMMARY : During an anatomical dissection of the suprahyoid region, we found an anomaly of the anterior belly of the digastric muscle. The anterior belly of the digastric muscle had bilateral double bellies and submental triangle had completely been filled by the anterior belly of the digastric muscle and medial bellies crossed over the mylohyoid raphe.*

*Key Words : Digastric Muscle, Anomaly, Submandibular Region.*

## INTRODUCTION

The digastric muscle which is situated on the floor of the mouth is called by this name because it has two bellies. The posterior belly of this muscle takes its origin in the temporal mastoid notch, and the anterior belly is attached to the mandible's digastric fossa. Both parts of this muscle lie through the hyoid bone and join to form a common tendon. The common tendon is anchored to the hyoid bone by a fibrous sling. Several studies have demonstrated the variations of the anterior bellies of the digastric muscle. With the introduction of new imaging modalities such as CT and MRI, these anatomical variants and anomalies have become important. In this study we observed a rare bilateral insertion and shape anomaly of the anterior belly of the digastric muscle. We decided to report this case since a variation of this type had not been published before.

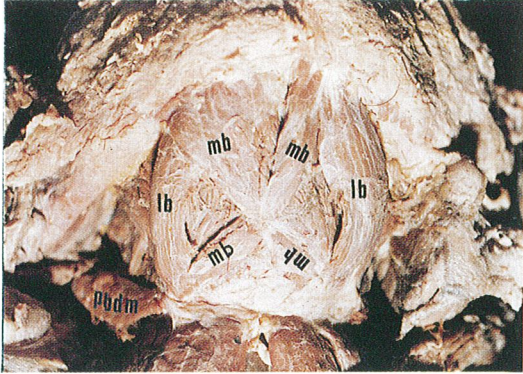
## CASE REPORT

During the anatomical dissection of the suprahyoid region of a white male cadaver of sixty

years of age and of 70 kilograms in weight, the anterior belly of the digastric muscle was observed having a bilateral double belly. The lateral bellies as in their normal course were attached to the lateral half of the ipsilateral digastric fossa. The medial bellies were inserted into the contralateral medial half of the digastric fossa crossing in the mylohyoid raphe. The medial bellies were divided into an anterior belly and a posterior belly. The medial belly crossing the midline became tendineous and fused with the mylohyoid raphe. The submental triangle was completely filled by the anterior belly of the digastric muscle (Fig. 1).

## DISCUSSION

The structures of the floor of the mouth are usually symmetrical. A lesion involving the motor branch of the trigeminal nerve, a tumor invasion developing in neighboring tissues or anatomical variants of the muscles on the floor of the mouth may lead to asymmetry (5). Anomalies of the anterior belly of the digastric muscle are known for more than one hundred years (8). Many authors describe supernumerary digastric muscles and term



mb: medial belly of the anterior belly of the digastric muscle, lb: lateral belly of the anterior belly of the digastric muscle, pbdm: posterior belly of the digastric muscle.

Fig - 1: Photograph of the anomalous anterior belly of the digastric muscle.

them accessory digastric muscles. Commonly these muscles are unilateral, some of which fuse with the mylohyoid raphe or cross the midline, insert into the contralateral digastric fossa (8, 9, 10). Sometimes the fibers of the accessory digastric muscle may unite the two anterior bellies of the digastric muscle (4). Mincna (7) found an anatomical anomaly of the digastric muscle in the submandibular region. Between the left and right anterior bellies of the digastric muscles, bilateral accessory digastric muscles were detected. These accessory digastric muscles originated from the ipsilateral digastric fossa, and as soon as crossing the midline, they were attached to the hyoid bone. Çelik et al. (3) found that both anterior bellies of the digastric muscles, especially the left one, had been enlarged. They were arranged as two parallel asymmetric bands extending from the hyoid bone to the chin. Çelik et al. (3) also observed that the anterior belly of the right digastric muscle had three separate insertions. The lateral and the median bands were attached to the digastric fossa on the same side. The most medial of these bands crossed the midline and inserted to the digastric fossa with the opposite digastric muscle. The variants of the anterior belly of the digastric muscle were also shown with CT and MRI (6).

In conclusion, it should be kept in mind that the anterior belly of the digastric muscle may have bilateral double belly and submental triangle may

completely be filled by the anterior belly of the digastric muscle and medial bellies may cross over the mylohyoid raphe.

Correspondence to : Dr.Mehmet ERSOY  
Ankara Üniversitesi, Sağlık Eğitim  
Fakültesi  
Fatih Cad. No : 197  
Asfalt - Keçiören  
06290 ANKARA - TÜRKİYE  
Phone : 312 - 380 06 04

#### REFERENCES

1. Arıncı K, Elhan A : Anatomî, 1.cilt, 1. baskı, Güneş Kitabevi, Ankara 1995; 187
2. Çelik H, et al : Bilateral anatomical anomaly of anterior bellies of digastric muscles, *Acta Anat Nippon* 1992; 67 : 650-665.
3. Çelik H, et al : Observation of anomalous triplication of unilateral anterior digastric muscle, *Clinical Anatomy* 1993; 6 : 353-355.
4. Du Bois RR : Beschreiburg einer anzahl muskel verietaten an einem individuum, *Anat. Anz* 1894; 9 : 451.
5. Larsson SG : Hemiatrophy of the tongue and floor of the mouth demonstrated by computed tomography, *J Comput Assist Tomogr* 1985; 9 : 914-918.
6. Larsson SG, Lufkin RB : Anomalies of digastric muscles, *Acta Anat* 1987; 11 : 422-425.
7. Mincna H : Anatomical anomaly of human digastric muscle, *Acta Anat* 1989; 134 : 263-264.
8. Testut L : Trattato di anatomia umana volume primo, Unione Tipografica Editrice, Torino 1894; pp : 68-70.
9. Triani M : Bilateral accessory digastric muscles, *Anat Clin* 1983; 5 : 199-200.
10. Waern A : Contribution a la connaissance des muscles interposes entre les ventres anterieurs des digastriques chez l'homme et presentation d'un projet de demonination pour ceux-ci., *Arch Anat Histol Embryol Strasb* 1935; 20 : 325-337