

HALLERMANN-STREIFF SYNDROME

A Case Report

Bilgin YÜKSEL, M.D., Güler ÖZER, M.D., Mustafa YILMAZ, M.D.

Çukurova University, Faculty of Medicine, Department of Pediatrics, Adana, Turkey
Gazi Medical Journal 6 : 87-90, 1995

SUMMARY : A 6 years 8 months old boy with Hallermann - Streiff Syndrome is described in this report. Presenting symptoms and signs are dyscephaly (an abnormal head structure with a bird-like face and hypoplastic mandible), microphthalmia, congenital cataract, a small nose, no eyelashes and eyebrows. There was malar hypoplasia. There was micrognathia and double chin, malocclusion of teeth, high palate and proportional short stature. His testicles were not in scrotum and could not be palpated in inguinal canals.

We report a case of Hallermann-Streiff Syndrome with classical findings and unilateral testicular hypoplasia and unilateral anorchy.

Key Words : Hallermann - Streiff Syndrome, Oculomandibulodycephaly.

INTRODUCTION

Hallermann - Streiff Syndrome (HSS), also known as oculomandibulodycephaly is a rarely seen disease (3). It was diagnosed by Hallerman in 1948 and by Streif in 1950 for the first time (7). In 1958, Francois (5) described seven basic findings as dyscephaly (an abnormal head structure with a bird-like face and hypoplastic mandible), abnormal teeth, proportional short stature, hypotrichosis, cutaneous atrophy, microphthalmia, and congenital cataract.

Etiology of HSS is unknown. All of the cases with classical HSS are reported to be sporadic (4), but as a cause the autosomal dominant mutation seems the most probable (8).

In this paper, we aim to report this case due to its rarity and included unilateral testicular hypoplasia

and we also want to review the available information about HSS.

CASE REPORT

A male patient (6 years 8 months) was admitted to our hospital with complaints of visual defect and short stature. The history revealed that he was born with a low birth weight (2000 grams). First teeth eruption was detected at three years of age. He had had a cataract operation when he was 6 months old. His parents were second generation relatives. However, there were no other people in the family with similar symptoms and findings. His eight-year-old sister was healthy.

Physical examination : The patient's weight was 12 kg (<3P), height 97 cm (<3P). He had a dimorphic facial structure with a protruding frontal bone, and also had bird-like face with a small nose, no

eyelashes and eyebrows (Fig 1, 2). There was sparse hair on the frontal and occipital areas of head. There was bilateral microphthalmia and horizontal nystagmus. The mouth was small and the palate had a high arch. There was malar hypoplasia. The ears were small and the mandible was hypoplastic with double chin. Teeth showed irregular dentition. His appearance was prepubertal male, testicles were not in scrotum and could not be palpated in inguinal canals (Fig 3). Other systemic findings were considered normal.

Laboratory studies : CBC, serum glucose, BUN, serum creatinine, serum electrolytes, liver function tests, thyroid function tests were normal.

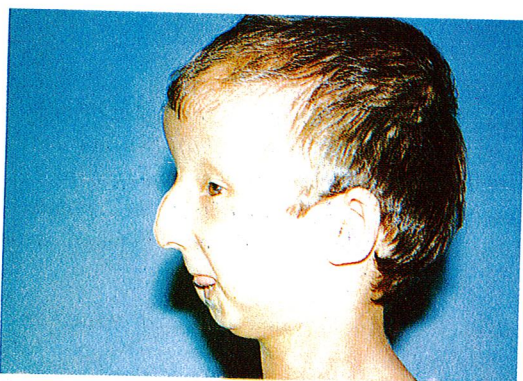

Fig - 1 : Abnormal head structure with a bird - like face and hypoplastic mandible.

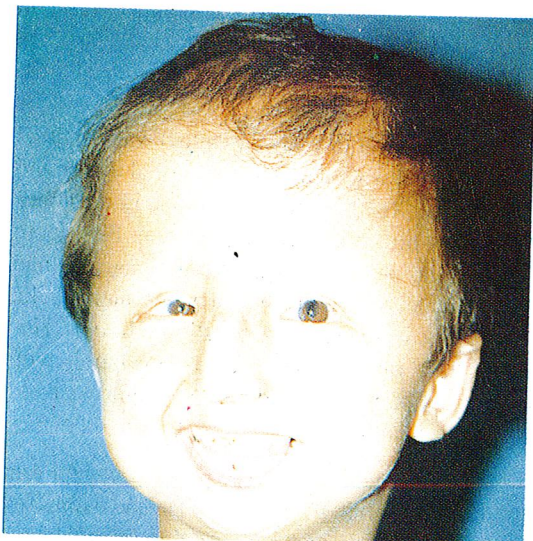

Fig - 2 : Frontal and occipital areas hair is sparse and there is alopecia is seen.

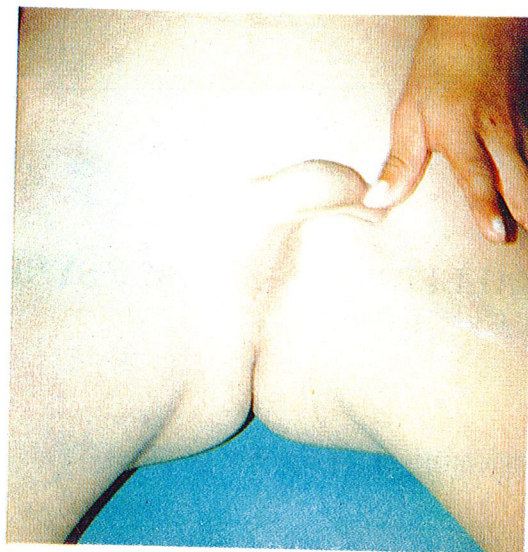

Fig - 3 : Testicles are not seen in scrotum.

Serum Ig A : mg/dl (33-mg/dl), IgE : 40 IU/ml (10-180 IU/ml), IgM : 109 mg/dl (43-207 mg/dl), IgG : 2851 mg/dl (608-1572 mg/dl), CD₄ (T₄) : % 32 (% 44.3), CD₈ (T₈) : % 39.2 (% 23.8), T₄/T₈ : 0.81, FSH : 4.28 MIU/ml, LH : 4.46 MIU/ml, Testosterone : 0.08 ng/ml. Abdominal ultrasonography was also normal. No testicles were observed in pelvic ultrasonography and tomography. X-rays of the wrist showed a bone age of 3.5 years. The long bones and metacarpals were thin and gracile with metaphyseal widening (Fig 4). In his head graphics, there was increase in vomian bones.

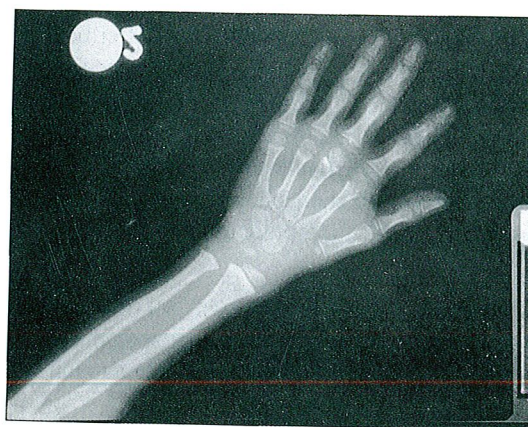


Fig - 4 : Thin and gracile radius, ulna and metacarpals with metaphyseal widening.

DISCUSSION

Over 150 cases of the Hallerman Streif Syndrome have been reported up to now (4). It has been reported that most of these cases are typical HSS cases with a characteristic facial structure and all of them are sporadic. In a few number of atypical HSS cases, there are familial characteristics and some of them are also reported to be sporadic (4). Higurashi and et al (6) have reported to have met one case with HSS in 27472 newborns. In the pedigree of our case, no other children with the same disease has been detected, and the following information presented in literature reveals a sporadic passage.

Thin and small face is called the bird-like face; small, mostly crooked nose which tends to be septal deviated and protrusion in frontal area are described as characteristics of these cases (4, 5, 7) and they are also present in our case.

Proportional short stature is seen in 45-68 % in these cases (5). Birth weight is normal in 64 %, prematurity and / or low birth weight occurring in the other 36 % (10). Short stature was also proportional and birth weight was 2000 grs in our case.

Hypotrichosis (80-90 %) (2, 10) is a frequently seen finding and especially in frontal and occipital areas hair is sparse and there is alopecia (9). As seen in the picture, our patient also has no eyebrows and eyelashes. In his frontal area his hair was rather sparse. However, cutaneous atrophy which is reported to be seen in 68-70 % of the cases (2) was not found in our case.

Balçı and Say (1) reported a patient with many dermatoglyphics features and bilateral simian lines. These features were not found in our case.

Frequently seen anomalies such as hypoplastic mandibula, double chin, high and narrow palate, small paranasal sinuses, no teeth, malformed teeth and malocclusion (4) were present in our case.

All three of the frequently seen ophthalmological finding of congenital cataract (81-90 %), microphthalmia (78-83 %), and nystagmus (32-45 %) (2, 4, 10) were also present in our case. However, strabismus and glom that are seen less frequently were absent.

Although 10-12 % of hypogenitalism has been reported in these cases (2), in our case, on physical examination neither in scrotum, nor in inguinal canal, testicles have been found. No testicles were ob-

served in pelvic ultrasonography and tomography. Human chorionic gonadotropin has been applied for a month. Nevertheless, no result is obtained. In operation, right testicle was found as hypoplastic in the inguinal canal but left testicle was not found. In literature (2, 5), cryptorchidism has been reported in these cases. However, there is no information about absence of testicles. We assume that unilateral anorchy can be considered as an additional finding in this case.

Mental retardation of different degrees has been seen at a proportion of 15 % in these cases (10). In the case, there was retardation of both mental and motor development.

Christian and et al (3) have described characteristic radiological findings. They have also reported that these findings will be helpful in diagnosis of the disease in newborns with HSS. According to them, the expected radiological bone findings in cases with HSS are : a skull characterized with width, malossification, widening in metaphyses, thin and gracile long bones and metacarpus with metaphyseal widening; and vertebra that are small at base. All these findings were present in our case.

Consequently, we conclude that the existence of unilateral anorchy can be considered as an additional finding in our case which is a typical HSS case with six findings out of the seven findings described by François, except for cutaneous atrophy.

Correspondence to : Dr.Bilgin YÜKSEL
Çukurova Üniversitesi Tıp Fakültesi
Balçalı Hastanesi
Pediatri Anabilim Dalı
01330 ADANA - TÜRKİYE
Phone : 322 - 338 60 60 / 3155

REFERENCES

1. Balçı S, Say B : Hallerman-Streiff Syndrome. The Turkish Journal of Pediatrics 1971; 13 : 165-172.
2. Barrucand D, Benradi C, Schmitt J : Syndrome de François. A propos de deux cas. Rev Oto Neuro Ophthal 1978; 50 : 305.

3. Christian CL, Lachman RS, Aylsworth AS, et al : Radiological findings in Hallerman-Streiff Syndrome : Report of five cases and a review of the literature. *Am J Med Genet* 1991; 41 : 508-514.
4. Cohen MM Jr : Hallerman-Streiff Syndrome : A review. *Am J Med Genet* 1991; 41 (4) : 488-499.
5. François J : A new syndrome : Dyscephalia with bird face and dental anomalies, nanism, hypotrichosis, cutaneous atrophy, microphthalmia and congenital cataract. *Arch Ophthalmol* 1958; 60 : 842-862.
6. Higurashi M, Oda M, Ijima K, et al : Livebirth prevalence and follow up of malformation syndromes in 27 472 newborns. *Brain Dev* 1990; 12 (6) : 770-773.
7. Smith DW : Recognizable patterns of human malformation, 3 th ed, Philadelphia. WB Saunders Company 1982; pp. 96-97.
8. Spaepen A, Schrandt SC, Fryns JP, et al : Hallerman-Streiff Syndrome : Clinical and psychological findings in children. Nosologic overlap with oculodentodigital dysplasia? *Am J Med Genet* 1991; 41 (4) : 517-520.
9. Sugar A, Bigger JF, Podos SM : Hallerman-Streiff-François Syndrome. *J Pediatr Ophthalmol* 1971; 8 : 234-238.
10. Suzuki Y, Fuji T, Fukuyama Y : Hallerman-Streiff Syndrome. *Dev Med Child Neurol* 1970; 12 : 496-506.