

# SONOGRAPHIC DEMONSTRATION OF INTESTINAL INVOLVEMENT IN HENoch-SCHÖNLEIN SYNDROME

Hakan ÖZDEMİR, M.D., Sedat IŞIK, M.D., Necla BUYAN\*, M.D., Enver HASANOĞLU\*, M.D.

Gazi University, Faculty of Medicine, Departments of Radiology and Pediatrics\*, Ankara, Turkey  
Gazi Medical Journal 6 : 27-29, 1995

**SUMMARY :** *We evaluated the efficacy of intestinal sonography in the diagnosis of gastrointestinal involvement of Henoch-Schönlein syndrome (HSS). Intestinal sonography was performed in twenty children who were clinically diagnosed as HSS and sonographic findings of the intestinal system were reviewed. Out of 20 patients, 10 who suffered from abdominal pain demonstrated sonographic findings consisted of intestinal involvement. Dilatation of intestinal segments, hypomotility, and excentric thickening of the intestinal wall were evaluated in the majority of the cases. Our results reveal that sonography of the intestine is useful in the evaluation of the intestinal involvement of HSS.*

**Key Words :** *Henoch-Schönlein Syndrome, Diagnosis, Ultrasonography, Intestinal Ultrasonography.*

## INTRODUCTION

Henoch-Schönlein syndrome (HSS) or anaphylactoid purpura is an acute allergic aseptic vasculitis of arterioles and capillaries (1). Although its etiology is unknown, drug exposure and previous infection have been implicated in some cases (12). There is a predilection for children and males (3). The disease mainly involves the skin, joints, gastrointestinal tract and kidneys. Purpuric rash, edema, polyarthritis, glomerulonephritis and gastrointestinal bleeding are the most frequent clinical findings (4). Abdominal pain is the most common gastrointestinal symptom, however, intestinal bleeding and intussusception may also occur. Diagnosis is based on clinical signs and symptoms (6, 10).

Although, radiographic (7) and computed tomographic (CT) (5, 14) demonstration of gastrointestinal (GI) involvement of HSS are well known, sonographic (US) findings have been described in

only a few instances (2). The purpose of our study was to assess the efficacy of US in the diagnosis of GI involvement of HSS and to determine the value of US in order to prevent unnecessary laparotomy.

## MATERIALS AND METHODS

Twenty children (13 boys and 7 girls) who were clinically diagnosed as HSS were evaluated for intestinal involvement with abdominal sonography between January 1991 and December 1993. The mean age was 10.5 ranging between 5 to 15 years. Clinical features of our patients were as follows; purpuric rash in 20 cases, arthritis in 9, hematuria in 7 and abdominal pain in 10 cases. Guaiacum positive stool was observed in the patients who had abdominal pain.

Intestinal structures were examined in transverse and longitudinal planes by using either 3.75 MHz or 7.5 MHz linear-array transducers (Toshiba SAL-55, Tokyo, Japan). In order to obtain a clear image

of intestinal structures, intestinal gas was moved by cautious massage with the transducer. Motility and dilatation of the intestinal segments, thickened wall of the small bowels and intramural hemorrhage were investigated.

## RESULTS

All of the patients who suffered from abdominal pain showed intestinal involvement with US. Abnormal intestinal findings consisted of, dilatation of the intestinal segments and hypomotility (10 cases), thickened intestinal walls (8 cases) (Fig 1), excentric thickened wall of the small bowel that gradually merged into a cockade phenomenon (4 cases) (Fig 2) and intramural hemorrhage (1 case). In the other patients who did not suffer from abdominal pain, we evaluated normal intestinal structures and these segments were compressible by moderate transducer pressure, and had normal motility. We did not detect massive intestinal hemorrhage or intussusception in all of our cases.

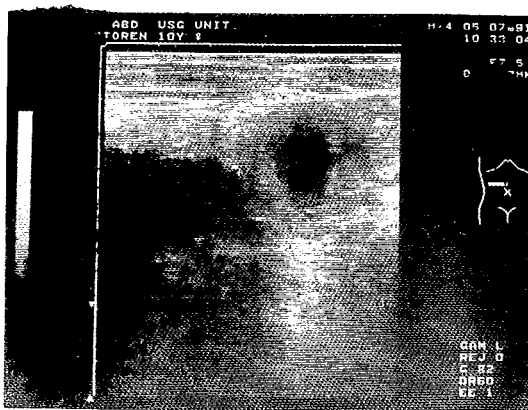


Fig - 1 : Transverse sonogram shows paralytic loop of the small bowel (arrows) in a child with HSS. The bowel wall is thickened (7 mm-between calipers).

## DISCUSSION

Henoch-Schönlein syndrome is a hypersensitivity angiitis mediated by immune complex deposition of IgA (14). Although its etiology is unknown, drug exposure and previous infection have been implicated in some cases (4, 12). It almost never occurs below the age of 2 years and it is equally rare over the age of 20 (12). The diagnosis is based on characteristic clinical signs and symptoms, as there are no laboratory tests that are specific (4). Syste-

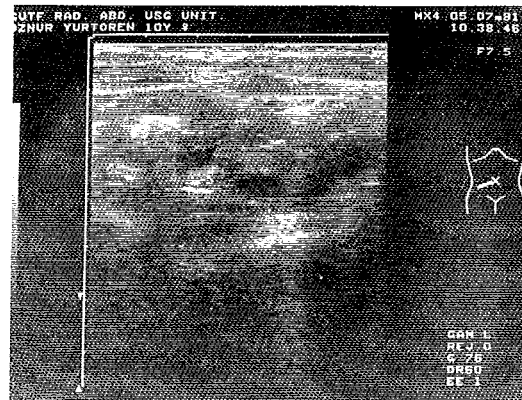


Fig - 2 : Transverse sonogram of the abdomen demonstrates cockade phenomenon with excentric thickened wall of the small bowel (arrows).

mic manifestations develop in 80 % of patients and in most the skin is most commonly affected with a characteristic leukocytoclastic vasculitis (6, 14). A nonthrombocytopenic purpuric rash is associated with joint, gastrointestinal and renal symptoms (14).

Gastrointestinal involvement occurs in up to 60 % of patients. Colicky abdominal pain, nausea, vomiting, diarrhea or melena are noted in 35 % - 60 % of cases (14). The gastrointestinal symptoms may govern the clinical picture or may appear as the first sign prior to skin lesions (11). The intestinal reaction usually resolves spontaneously, however perforation or intussusception and obstruction may occur (9). Pathologically, the most common abnormality in the gastrointestinal tract is submucosal and mural infiltration of the bowel by blood or edema fluid. Microscopically, changes of a vasculitis are seen with endothelial proliferation and thrombosis of small arterioles (6).

Radiographic findings in HSS are nonspecific and can also simulate nonhemorrhagic conditions such as lymphoma and regional enteritis (15). Radiographically, the disease usually causes small bowel involvement manifested as fold thickening which may be smooth or irregular, prolongation of transit time and increased distance of intestinal loops as indirect sign of intramural edema (6, 7). Edema and intramural bleeding are thought to account for the radiographic appearance of submucosal indentations. Spasm and ulceration are prominent.

With healing, the radiographic findings revert to normal; fibrosis and stricture do not occur (14). When skip areas, narrowing and ulceration are present in HSS without the characteristic thumbprinting, the similarity to Crohn's disease can be striking (8). In contrast HSS is a self-limiting process; the small-bowel abnormalities rapidly return to normal.

CT and sonographic demonstration of intestinal involvement of HSS have been reported in only a few cases (2, 5, 12). Although no exact criterion has been agreed upon for the normal thickness of the small bowel, 3 mm is presumed to be the upper limit of normal.

Our results show that intestinal involvement in HSS is associated with dilatation of the intestinal segments, hypomotility and excentric thickening of the intestinal walls in the majority of the cases. In one of our cases we demonstrated intramural bleeding as an anechoic area in the intestinal wall. Although we did not evaluate any unusual complications such as intussusception and obstruction, patients with HSS may demonstrate these complications (2, 7). Therefore, intestinal sonography is useful in follow-up examinations of patients with HSS. Also with the help of sonographic demonstration of intestinal involvement, it can be possible to come to a decision in order to start the corticosteroid treatment, as this may have a role in hastening the resolution of self-limited pain (13).

Roentgenographic and sonographic manifestations of nonhemorrhagic gastrointestinal disorders such as regional enteritis may mimic HSS, however, rapidly changing enlargement of the intestinal walls at control examination and the more pronounced segmental manifestations in HSS can make prompt differentiation (6, 8).

In conclusion, our study demonstrates the utility of intestinal sonography for the detection of intestinal manifestations of HSS, especially intramural bleeding and its complications, and may decrease the rate of unnecessary laparotomy. Furthermore, it is technically a simple and quick examination and may prevent unnecessary ionizing radiation in children.

Correspondence to : Dr.Hakan ÖZDEMİR  
Gazi Üniversitesi Tıp Fakültesi  
Radyoloji Anabilim Dalı  
Beşevler  
06500 ANKARA - TÜRKİYE  
Phone : 312 - 214 10 00 / 5156

#### REFERENCES

1. Allen DM, Diamond LK, Howell DA : Anaphylactoid purpura in children (Schönlein-Henoch syndrome). *Am J Dis Child* 1960; 99 : 833-854.
2. Bömelburg T, Claasen U, Von Lengerke HJ : Intestinal ultrasonographic findings in Schönlein-Henoch syndrome. *Eur J Pediatr* 1991; 150 : 158-160.
3. Cameron JS : Henoch-Schönlein purpura : clinical presentation. *Contr Nephrol* 1984; 40 : 246-249.
4. Cream JJ, Gumpel JM, Peachey RDG : Schönlein-Henoch purpura in the adult : a study of 77 adults with anaphylactoid or Schönlein-Henoch purpura. *Q J Med* 1970; 39 : 461-468.
5. Demirci A, Cengiz K, Barış S, Karagöz F : CT and ultrasound of abdominal hemorrhage in Henoch-Schönlein purpura. *J Comput Assist Tomogr* 1991; 15 (1) : 143-145.
6. Glasier CM, Siegel MJ, McAlister WH, Shackelford GD : Henoch-Schönlein syndrome in children : gastrointestinal manifestations. *AJR* 1981; 136 : 1081-1085.
7. Handel J, Schwartz S : Gastrointestinal manifestations of the Schönlein-Henoch syndrome : roentgenologic findings. *Am J Dis Child* 1957; 78 : 643-652.
8. Kaftori JK, Pery M, Kleinhaus U : Ultrasonography in Crohn's disease. *Gastrointest Radiol* 1984; 9 : 137-142.
9. Lindenauer SM, Tank ES : Surgical aspects of Henoch-Schönlein's purpura. *Surgery* 1966; 59 : 982-987.
10. Mamedow IM, Aiev SA : Errors in the diagnosis of acute abdomen in hemorrhagic vasculitis. *Klin Khir* 1988; 2 : 51-54.
11. Meadow SR, Scott DG : Berger disease : Henoch-Schönlein syndrome without the rash. *J Pediatr* 1985; 106 : 27-32.
12. Nielsen HE : Epidemiology of Schönlein-Henoch purpura. *Acta Pediatr Scand* 1988; 77 : 125-131.
13. Rosenblum N, Winter HS : Steroid effects on the course of abdominal pain in children with Henoch-Schönlein purpura. *Pediatrics* 1987; 79 : 1018-1021.
14. Siskind BN, Burrell MI, Pun H, Russo R, Levin W : CT demonstration of gastrointestinal involvement in Henoch-Schönlein syndrome. *Gastrointest Radiol* 1985; 10 : 352-354.
15. Yentis I : Henoch-Schönlein purpura mimicking acute appendicitis and Crohn' disease. *Br J Radiol* 1973; 46 : 555-556.