

# INCIDENCE OF INTERPARIETAL AND PREINTERPARIETAL BONES IN ADULT SKULLS FROM CENTRAL ANATOLIA REGION

Rabet GÖZİL, Ph.D., Engin ÇALGÜNER, Ph.D., Semih KESKİL, M.D.

Gazi University, Faculty of Medicine, Department of Anatomy Ankara, Turkey  
Gazi Medical Journal 5 : 123-125, 1994

**SUMMARY :** *The study was conducted on 224 adult Anatolian skulls which were examined for the presence of interparietal and preinterparietal bones. Only 4 interparietal bones were found (1.8% of the present series) while a single preinterparietal bone was found in 6 skulls (2.7 %) and multiple preinterparietal bones in 5 skulls (2.2 %). Their location and possible derivation are briefly discussed.*

**Key Words :** *Preinterparietal Bone, Skull, Interparietal Bone.*

## INTRODUCTION

There is some controversy in the literature concerning the limits and ossification of the membranous portion of the occipital bone, known as the interparietal in man. Phylogenetically, the interparietals fuse with the parietals in marsupials, ruminants and ungulates; while in rodents they fuse both with the occipital and the parietal bones (5). In mammals they persist as a separate bone (3). In primates and the carnivora, as in man, they fuse with the occipital. But sometimes, as an anomaly in man, the interparietal is seen as a separate bone. Hamilton (3) has mentioned that, the interparietal bone, Os Incae is characteristic of the inhabitants of ancient Peru. The location of preinterparietal bones and the Inca bones is quite different, especially in the position of their bases. Differentiation of a pre-interparietal bone from a sutural bone and from other variations in the interparietal region is important because of the increased use of these bones in classification of non-metric cranial variants for separation of population (8).

Pal et al (7) found that the preinterparietal ossicles were separated from the lower part of the squamous occipital by a transverse suture on the lower edge which was more than 4 cm above the external occipital protuberance. They also observed that the distance between the lambda and the external occipital protuberance in these skulls ranged from 7 to 8 cm (7). In another type the bones are situated in the posterior end of the sagittal suture. On the other hand, the lower edges of the interparietal bones were usually situated slightly above the external occipital protuberance.

Sutural "Wormian" bones are detached bony ossicles (6) and, most of the sutural bones appear in the narrow space between the parietals and the interparietals. No sutural bone in the lambda region form a triangular territory and none of the sutural bones cause an apparent depression on the upper edge of the interparietals. They have an apparently irregular arrangement.

The present study was undertaken to observe the incidence of interparietal bones in skulls from the Central Anatolia region, hitherto unreported.

### MATERIALS AND METHODS

The material for this study comprised 224 adult Anatolian skulls obtained from the collections of the Department of Anatomy, Gazi University Medical School and the Department of Physical Anthropology, Ankara University Faculty of Language, History and Geography. The skulls were studied for the presence of single or multiple interparietal and preinterparietal bones. The observations were mainly performed macroscopically but, when necessary, a magnifying glass was used.

### RESULTS

Adult skulls displayed various anomalies in the interparietal part of the occipital squama. In 15 out of the 224 skulls examined, single or multiple separated bones were observed. Their individual incidences were calculated and recorded (Tables 1 and 2).

The present study shows the occurrence of interparietal bone, with an incidence of 1.9%. This is high compared to the incidence of 0.4% in adult skulls of India (10) but in parallel with the incidence of 2.5% in adult skulls of the Nigerian series (11).

### DISCUSSION

From the observations recorded above and the information gathered from the previous workers (4, 5), it is evident that the faulty ossification of the squamous part of the occipital bone may lead to the persistence of fairly wide varieties of abnormalities in the adult occipital bones, particularly in the region of squamous part or in the vicinity of lambdoid suture. All the varieties of interparietal bones in the adult skulls have been explained on the basis of presence of more than one center of ossification for the

Present	Number of cases	Percentage
Single	4	1.8
Multiple	0	0
Unilateral	1	0.5

Table 1 : Interparietal bone.

Present	Number of Cases	Percentage
Single	6	2.7
Multiple	5	2.2

Table 2 : Preinterparietal bone.

squamous part of occipital bone above the highest nuchal lines and the failure of fusion of one or more of these centers with the adjacent component of the bone.

Ranke (9) had described the interparietal part as developing from 3 pairs of ossification centers (Fig 2) and occasionally an additional 4th pair appearing at the upper angle of the interparietal part. On the other hand, other investigators reported that 2 pairs of ossification centers form the interparietal part and defined the additional pair as a primordium of the interparietal bone (2). The interparietal part of squamous occipital bone above the highest nuchal line develops in membrane, usually from two pairs of centers (Fig 1) (2). The first pair of centers appears above the supraoccipital cartilage and forms two lateral plates of bone. A second pair of centers (one center on either side of the midline) appears between the two lateral plates and these fuse to form the central portion of the interparietal bone. This is a large part of the bone extending from the lambda to a little distance above the external occipital protuberance (Fig 3). In addition to these two pairs of centers which form the interparietal bone, occasionally a third pair of centers (preinterparietal) appears near the upper angle of the bone (7, 9). The ossicles developed from this occasional 3rd pair of centers have been termed preinterparietals (11). The supraoccipital part develops in cartilage and is situated between the nuchal lines and the posterior margin of the foramen magnum.

As a closing remark (9), it must be stated that the ossicles in the region of the lambda may fuse into the neighboring bones after 40 years of age, leaving

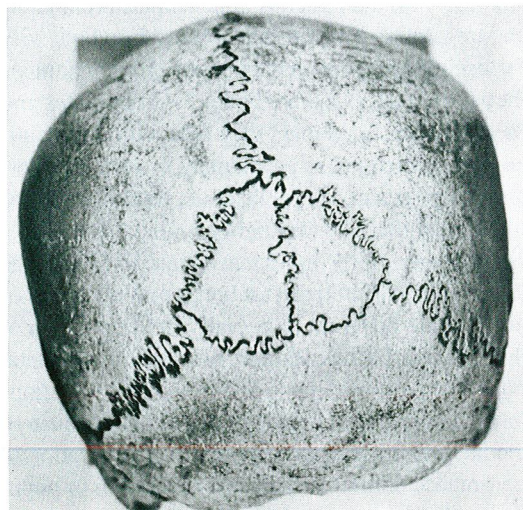


Fig - 1 : Preinterparietal bones forming two lateral pieces.

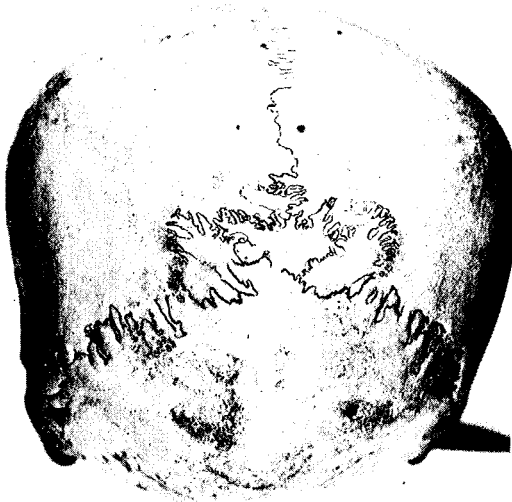

Fig - 2 : Multiple preinterparietal bones.

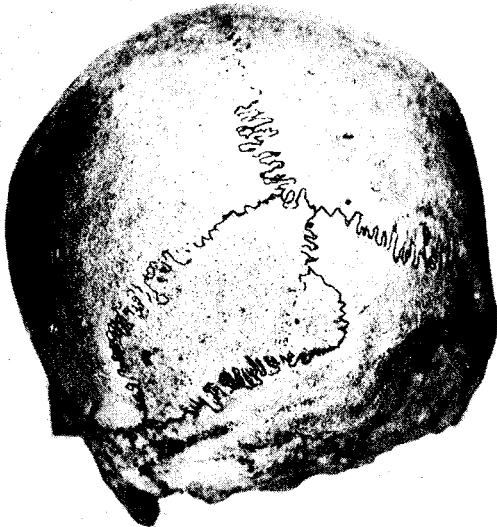


Fig - 3 : Here three fourths of the interparietal forms a separate unilateral bone.

irregular sutures between them. The issue thus still remains as to how to identify the aforementioned bones in the adult, especially in the skulls from individuals of advanced age, although they can be clearly differentiated at younger ages .

Correspondence to : Dr.Rabet GÖZİL  
Gazi Üniversitesi Tıp Fakültesi  
Anatomi Anabilim Dalı  
Beşevler  
06500 ANKARA - TÜRKİYE  
Phone : 312 - 214 10 00 / 6929

#### REFERENCES

1. Fakhruddin S, Bhalerao UK : Interparietal bone in three pieces. A case report. J of Anatomical Society of India. Allahabad XVI 1967 ; 3 : 146-147
2. Gopinathan K : A rare anomaly of 5-ossicles in the preinterparietal part of the squamous occipital bone in north Indians. J Ana 1992 ; 180 : 201-202.
3. Hamilton WJ : Text Book of Human Anatomy. 2nd ed. The MacMillan Press Ltd, London 1976; pp. 71-84.
4. Jones FW : Buchanans Manual of Anatomy. 7th ed Bailliere Tindall and Co, London 1960 ; pp. 226-229.
5. Keith A : Human Embryology and Morphology. 6th ed. Edward Arnold and Co, London 1948 ; pp. 212-224 (Cited in Ref. No : 8).
6. Kolte DT, Mysorekar VR : Tripartite interparietal bone. J. of Anatomical Society of India. Allahabad XV 1966 ; 96.
7. Pal GP, Tamankar BP, Routal RV, Bhagwat SS : The ossification of the membranous part of the squamous occipital bone in man. J Ana 1984 ; 138 : 259-266.
8. Pal GP, Bhagwat SS, Routal RV : A study of sutural bones in Gujarati (Indian) crania. Anthro Anz 1986 ; 44 : 67-76.
9. Ranke J : Uber das interparietale und die verknocherung des Schädeldachs beim Affen. (Cited in Ref. No : 8).
10. Singh PJ, Gupta CD, Arora AK : Incidence of interparietal bones an adult skulls of agra region. Anat Anz 1979 ; 145 : 528-531.
11. Saxina SK Chowdhary DS, Jain SP : Interparietal bones in Nigerian skulls. J Anat 1986; 144 : 235-237.