

A CASE OF GROWTH HORMONE DEFICIENCY THAT ACCOMPANIES THE RUSSELL-SILVER SYNDROME

Handan ALP, M.D., Naci CEVİZ, M.D., Memduh AKYÜZ, M.D., Hayrettin YILMAZ, M.D.

Atatürk University, Faculty of Medicine, Department of Pediatrics, Erzurum, Turkey
Gazi Medical Journal 5 : 149-152, 1994

SUMMARY : *The constellation of prenatal and postnatal growth retardation with or without asymmetry, normal head circumference, triangular facies, and normal psychomotor development has become known as the Russell-Silver syndrome. The causes of growth retardation in Russell-Silver syndrome are not known. To our knowledge, 8 cases of Russell-Silver syndrome accompanied by growth hormone deficiency have been reported.*

We diagnosed a girl, aged 13 years, with hemihypertrophy, triangular facies, frontal bossing, short stature, mental retardation and thoraco-lomber scoliosis as Russell-Silver syndrome. Her fasting growth hormone level was 1.7 ng/ml. Maximum growth hormone level after stimulation by L-dopa was 1.9 ng/ml at the 90 th minute, and 2.5 ng/ml at the 30 th minute after stimulation by insulin, with a glucose level of 40 mg/dl. The case was considered as Russell-Silver syndrome with growth hormone deficiency.

Key Words : *Russell-Silver Syndrome, Growth Hormone Deficiency.*

INTRODUCTION

Silver et al described 2 cases with intrauterine growth retardation, postnatal growth retardation, body asymmetry, and normal psychomotor development in 1953. One year later Russell reported five cases with prenatal and postnatal growth retardation, triangular facies, disproportioned shortening of upper limbs, and fifth finger clinodactyly; and only two of those five patients had limb length asymmetry. Since these two reports, the constellation of prenatal and postnatal growth retardation with or without asymmetry, normal head circumference, triangular facies, and normal psychomotor development has become known as the Russell-Silver Syndrome (RSS) (11, 13). In the following years, some other components have been added, and it

has been reported that some components, defined previously, may not be accompanied by the syndrome (3, 12).

The causes of growth retardation in RSS are not known. To our knowledge, 8 patients have been reported to have RSS that was accompanied by growth hormone deficiency (1, 5, 8, 9, 10, 12). This case is reported to draw attention to the increasing constellation of RSS and growth hormone deficiency.

CASE REPORT

She was a girl aged 13 years, the admitted to the pediatric outpatient clinic the body asymmetry that was prominent on the right arm and leg, present since birth. Since previous medical records were not

available, we were unable to obtain enough knowledge about the perinatal period and about the growth curves. She was said to have low birth weight in comparison with the other children of the family.

The mother was 50 and the father was 55-years-old. They were not relatives. The mother had nine deliveries. Of these nine children, 3 had died due to unknown reasons within 2-3 years. The case was the 5 th child of the parents and there was not any history of similar signs in the other family members. The weight of the father was 57 kg and the height 170 cm. We could not examine the other members of the family, therefore their height and weight measurements were not available.

Her weight was 30 kg, height 138 cm (both below the 3 rd percentile) (7) and head circumference 55 cm (between the 50 th and 98 th percentiles) (4). Hemihypertrophy that was apparent on the right arm and leg and on the left hemithorax, craniofacial disproportion, frontal bossing, triangular facies, and thoraco-lomber scoliosis were the other signs (Fig 1, 2, 3).

Her urinalysis, with an overnight specific gravity of 1020, hemogram, erythrocyte sedimentation rate, renal function, liver function, serum electrolyte, T₃, T₄, TSH, Free T₃, Free T₄ values were all in normal limits. Skull radiographs showed impressio digitale and widening of diploe on frontal bone and sella had normal appearance. Radiographs of columna vertebralis showed thoraco-lomber scoliosis and spina biphida on the 1st sacral ver-

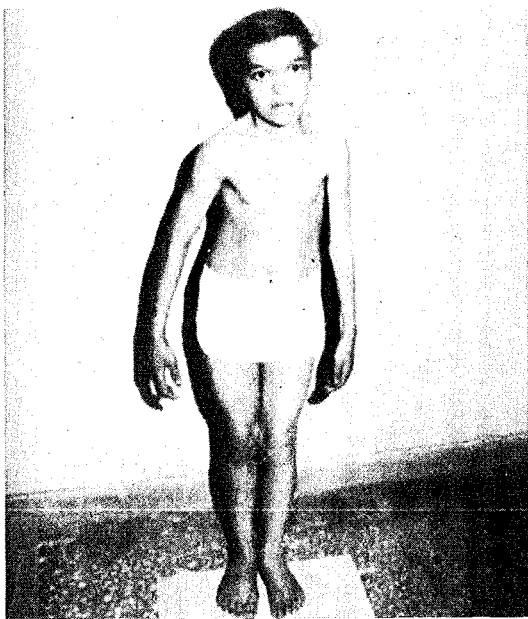


Fig - 1

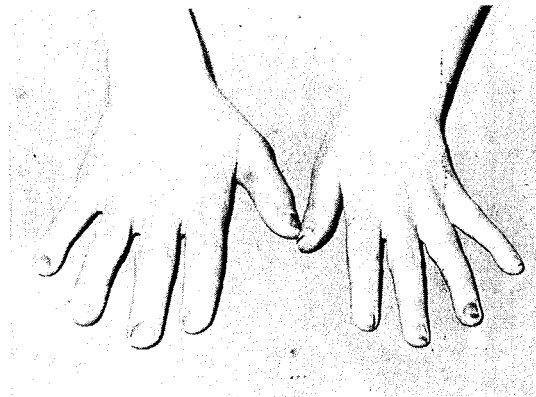


Fig - 2

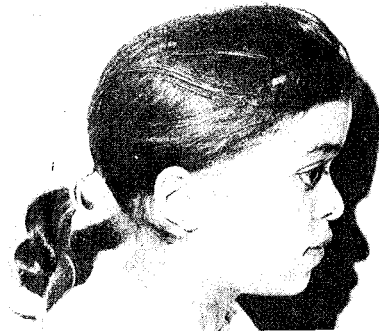

Fig - 3

tebra. There were no pathologic signs on intravenous pyelography (IVP), abdominal ultrasonography, electroencephalogram, VUCG, computed tomography of brain, pituitary gland and abdomen. Bone age was 11 years (6).

The fasting growth hormone level was 1.7 ng/ml. Growth hormone levels at the 30 th, 60 th, 90 th and 120 th minutes after stimulation by L-dopa were 1.5 ng/ml, 1.8 ng/ml, 1.9 ng/ml and 1.7 ng/ml, respectively. The maximum growth hormone level after stimulation by insulin was 2.6 ng/ml at the 30 th minute with a simultaneous serum glucose level of 40 mg/dl. Chromosome analysis was normal, 46, XX.

Her intelligency quotient that was detected by the Stanford-Binet intelligence scale was 56, and organic signs together with immaturity were observed on Bender-Gestalt visual motor perception test and Goodenough test. Her mental age was 6 years.

With the signs of craniofacial disproportion, frontal bossing, triangular facies, hemihypertrophy, short stature, mental retardation, and with the results of growth hormone stimulation tests; she was thought to have growth hormone deficiency that accompanies the RSS. As the family was unable to obtain growth hormone, we could not start the treatment.

DISCUSSION

There are a lot of reports on RSS. The most comprehensive is the Tanner's in which he and associates have reported a longitudinal study of thirty-nine cases having RSS. They discussed the birth weight and height, head circumference, bone age, growth scores for years, skinfolds and limb length together (13).

The causes of growth retardation in RSS are not known (8). The growth deficiency in RSS is of prenatal onset and appears to involve others tissues besides the skeleton. The possibility of the growth disturbance being related to relative lack of growth hormone secretion has been raised by Tanner and Ham based on their observations of 2 children with this disorder who were empirically treated with growth hormone (3). A patient with apparent RSS and documented growth hormone deficiency was reported for the first time in 1970 (9).

We are aware of 8 cases reported as RSS accompanied by growth hormone deficiency (1, 5, 8, 9, 10, 12). Five of them had idiopathic growth hormone deficiency (8, 9, 10) and one had growth hormone deficiency due to a craniopharyngioma (1). In one of the five cases; breech birth, asphyxia at birth and prolonged jaundice were thought to be responsible for the idiopathic growth hormone deficiency (8). There were no information about the cause of the growth hormone deficiency in the remaining two cases.

In our case, we could not detect any pathologic finding in pituitary gland. Although we were unable to get enough information about the perinatal period, she seems to have an idiopathic growth hormone deficiency.

Since complicated pregnancy, cyanosis at birth, a low Apgar score and neonatal prolonged jaundice have been reported frequently in RSS, and because of the increasing constellation of growth hormone deficiency and RSS; it is possible that RSS with growth hormone deficiency may be more common than previously realized (8, 9). Therefore, patients with RSS, whose growth are below the 3rd percentile, should have a complete endocrinologic evaluation including growth hormone.

Correspondence to : Dr.Handan ALP
Atatürk Üniversitesi Tıp Fakültesi
Çocuk Sağlığı ve Hastalıkları
Anabilim Dalı
ERZURUM - TÜRKİYE
Phone : 442 2331122 / 1415

REFERENCES

1. Draznin MB, Stellin MW, Johanson AS : Silver-Russell Syndrome and craniopharyngioma. *J Pediatr* 1980; 96 : 887-889.
2. Fuleihan DS, Der Kabustian VM, Najjar SS : The Russell-Silver Syndrome : Report of three sibilings. *J Pediatr* 1971; 78 : 654-657.
3. Gareis FJ, Smith DW, Summitt RJ : The Russell-Silver syndrome without asymmetry. *J Pediatr* 1971; 79 : 755-781.
4. Greenberg MS : Handbook of Neurosurgery (Greenberg Graphics Inc., Calceland) 1994; p. 1.
5. Hall SG : Microphallus, growth hormone deficiency and hypoglycemia in Russell-Silver syndrome. *Am J Dis Child* 1978; 132 : 1149.
6. Meschan I : Basic concepts regarding the radiographic study of bones and joints, in : Roentgen signs in diagnostic imaging, ed. Meschan I (WB Saunders Company, Philadelphia) 1985; pp. 1-54.

7. Neyzi O, Günöz H : Büyüme ve gelişme bozuklukları, in : *Pediatric*, eds. O Neyzi, T, Ertuğrul (Nobel Tıp Kitabevleri, İstanbul) 1993; pp. 69-114.
8. Nishi Y, Kawaguchi S, Nakanishi Y, Usui T : Silver-Russell Syndrome and growth hormone deficiency. *Acta Paediatr Scand* 1982; 71 : 1035-1036.
9. O'Brien JE, Nejad AS, Feingold M : Growth hormone deficiency in a patient with Russell-Silver Syndrome. *J Paediatr* 1978; 93 : 152-153.
10. Pintor C, Loche S, Puggioni R, et al: Growth hormone response to hpGRF-40 in different forms of growth retardation and endocrine metabolic diseases. *Eur J Paediatr* 1986; 144 : 457-481.
11. Saal HM, Pagon RA, Pepin MG : Reevaluation of Russell-Silver syndrome. *J Paediatr* 1985; 107 : 733-737.
12. Subklew D, Höck S : Zahn-und kieferent wicklung beim Silver-Russel-Syndrom. *Fortschr Kieferorthop* 1990; 51 : 378-383.
13. Tanner JM, Jejjarage H, Laveron N : The natural history of the Russell-Silver Syndrome : A longitudinal study of thirty-nine cases. *Paediatr Res* 1975; 9 : 611-623.