

THE ROLE OF FLEXOR DIGITORUM SUBLIMIS VINCULUM AT THE PROXIMAL INTERPHALANGEAL JOINT*

M.Mümtaz GÜLER*, M.D., D.A. McGROUTHER**, M.D.

GATA Military Medical School, Department of Plastic and Reconstructive Surgery*,
Ankara, Turkey
University College London, Department of Plastic Surgery**, London, England
Gazi Medical Journal 3 : 1-4, 1992

SUMMARY : *The vinculum of the flexor digitorum sublimis has been found to apply traction to the volar plate on flexion of the joint.*

Key Words : *Vincula Brevia, PIP Joint, Volar Plate.*

INTRODUCTION

The role of the vincula in providing nutrition for the flexor tendons has been well described (Brockis, 1953; Gad, 1967; Idler, 1985; Lundborg, 1977,1978; Strauch, 1985). Gray's Anatomy describes the vincula of the flexor tendons as being of two types (Warwick and Williams, 1973). The vincula longa are threadlike slips, of which two are usually attached to each tendon of the flexor digitorum superficialis and one to each tendon of the flexor digitorum profundus. The vincula brevia, two in number, are described as triangular bands attached to the deep surfaces of the tendons close to their insertions (Leffert et al. 1974). The vincula brevia seem to be more extensive structures than would be necessary to carry vessels and it seems possible that they have a mechanical role in addition.

A series of cadaver dissections has been performed to investigate the way in which the structures at the proximal and of the volar plate fold and interact on flexion of the joint. Particular attention has been paid to the dynamic changes in shape and structure of the vincula brevia at the neck of the proximal phalanx.

MATERIALS AND METHODS

Eight proximal interphalangeal joints have been dissected in detail in frozen cadaveric specimens. In each case the volar skin has been incised at the midline, retracted laterally and resected. Grayson's (1940) and Cleland's (1978) ligaments have been divided as necessary to allow free motion of the joints. The constituent parts of the flexor tendon sheath have been identified according to the common pattern described by Doyle and Blyth (1977).

The first step in approaching the joint was excision of the C2 and C3 pulleys to expose the profundus flexor tendon. This tendon was then divided distal to the proximal interphalangeal joint. The long vincula, a thin strand of vessel surrounded by connective tissue, was divided and the profundus tendon retracted proximally into the palm to remove it from the sheath. This manoeuvre provided an uninterrupted view of the flexor sublimis tendon, by observing from the lateral aspect of the digit the volar plate and vinculum could be visualised during an entire range of simulated active motion of the proximal interphalangeal joint, by traction on the flexor sublimis tendon in the palm. In some cases

the distal A2 pulley was released and retracted to provide further exposure.

RESULTS

The vinculum was found to be comprised of a loose network of criss-cross sign fascial fibres forming a loose three-dimensional trellis. On extension the fibres of the vinculum were found to become tight in a proximo-distal bone-to-tendon configuration. In the resting (semiflexid) posture they were found to be roughly perpendicular from bone to tendon and in flexion tight in a distal-proximal bone-to-tendon pattern. Excursion studies show that for 100 degrees of proximal interphalangeal flexion the tendon attachment would be expected to glide 14 mm (middle finger) (McGrouther and Ahmed, 1981).

In every case it was observed that as the flexor sublimis moved proximally traction was exerted on the vinculum (Fig 1 a, b,c) which became taut and in turn applied traction to the proximal end of the volar plate.

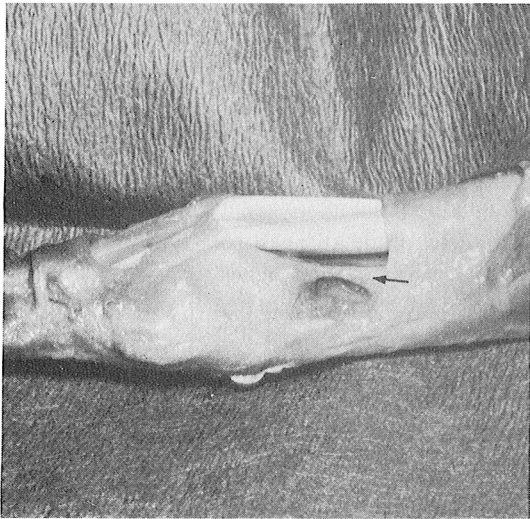


Fig. 1 : Lateral view of PIP dissection (the arrows show the vinculum and check rein ligament).
a. On full extension : the check rein ligament is taut.

The net effect was that the vinculum controlled the movement of the volar plate as though to pull it out of the joint on flexion. There after the flexor sublimis was divided at its insertion and by applying traction to the proximal end of the tendon (Fig 2 a, b) it was possible to demonstrate more effectively the traction through the vinculum on the proximal edge of the volar plate (Fig 3 a, b). This was not

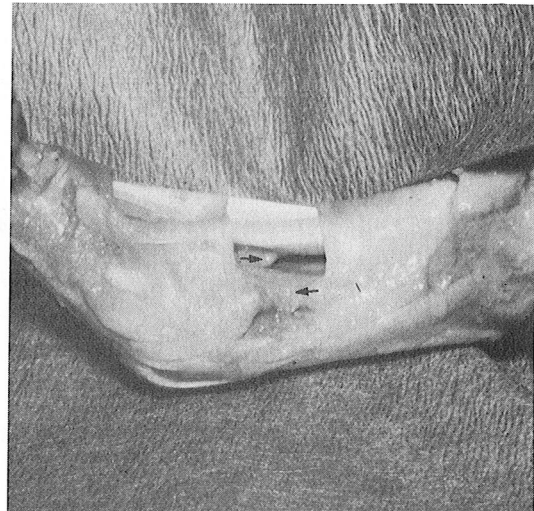


Fig. 1 : b. Mid flexion : - the check rein ligament is slack and the FDS vinculum is seen.

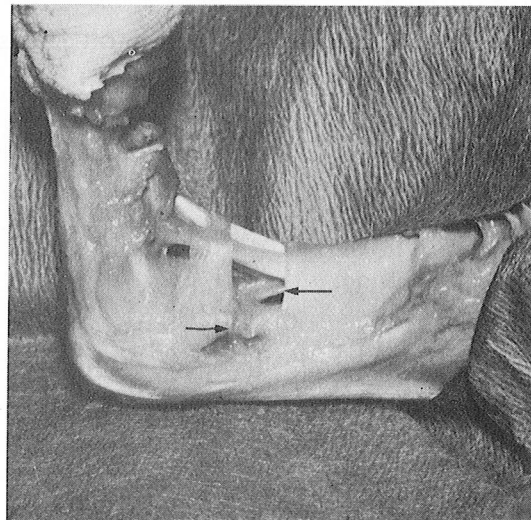


Fig. 1 : c. 90° Flexion : the vinculum is taut and applying traction to the volar plate.

sufficient to flex the joint without some passive external assistance. Finally, the vinculum was divided and again by applying traction to the vinculum the movement of the volar plate could be observed.

At the completion of these tests the loose areolar tissue which comprises the vinculum was removed and the presence of the laterally placed check-rein ligament was confirmed (Bowers et al. 1980; Eaton, 1971; Watson et al. 1979) (Fig 4). These were, however, very difficult to identify in fixed cadaveric material.

DISCUSSION

The vinculum appears to be a loose meshwork

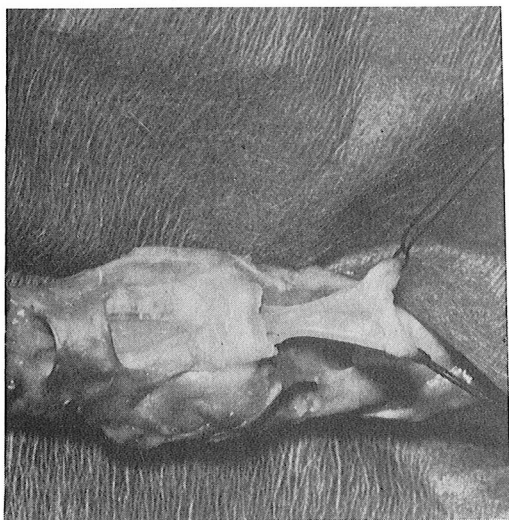


Fig. 2 : Volar view of PIP joint : -
a. FDS divided the loose meshwork of the vinculum is seen merging with the volar plate.

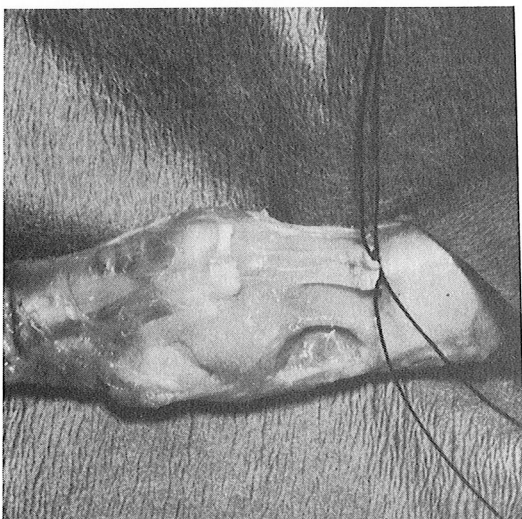


Fig. 2 : b. In applying traction the pull of the vinculum on the volar plate is demonstrated.

of material which becomes tight in full extension of the joint contributing with the check-rein ligaments to a block to full extension. On flexion of the joint the vinculum applies traction to the volar plate. The change in configuration from flexion to extension is due to the loose three-dimensional arrangement of the fibres within the vinculum. This appears to be a system which would be very vulnerable to damage by oedema and fibrosis. It may contribute to proximal interphalangeal contracture.

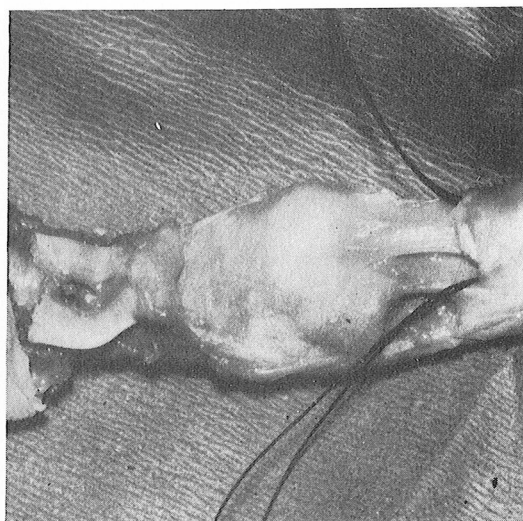


Fig. 3 : Oblique view : -
a. The FDS has been divided and has retracted.

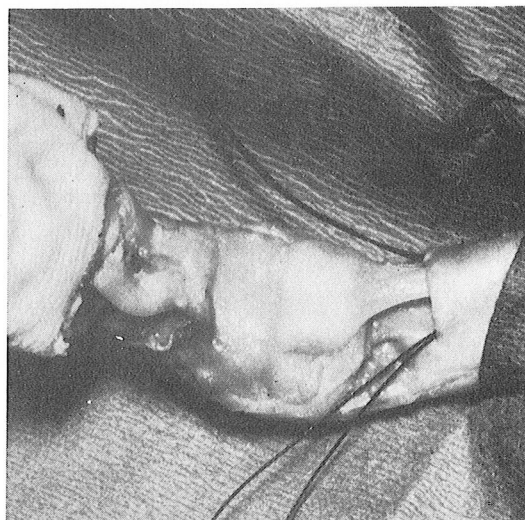


Fig. 3 : b. By traction in the FDS the pull of the vinculum in the volar plate is seen.

* Studied in Canniesburn Hospital (Glasgow - Scotland) and presented at XII. National Congress of Turkish Plastic and Reconstructive Surgery in Kuşadası, 27 - 30 October, 1990.

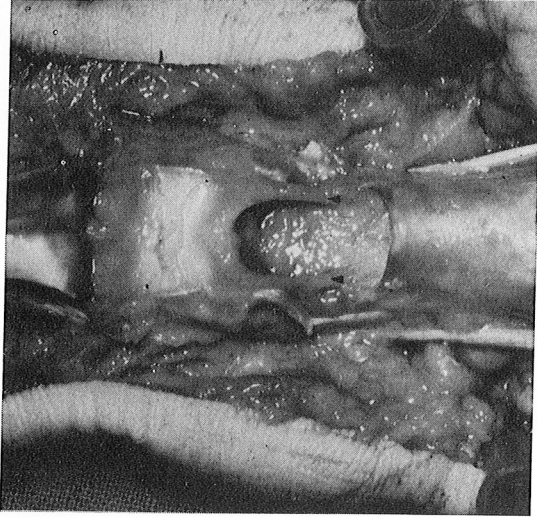


Fig. 4 : Volar view of check rein ligaments (shown by the arrows).

8. Idler RS : Anatomy and biomechanics of the digital flexor tendons *Hand Clin* 1 : 3-11, 1985
9. Leffert DR, Weis C, Athanasoulis CA : The vincula with particular reference to their vessels and nerves. *J Bone and Joint Surg* 56A : 1191-1198, 1974
10. Lundborg G : The vascularisation of human flexor tendons with the digital synovial sheath region. *J Hand Surg* 2 : 417-426, 1977
11. Lundborg G : Experimental extrinsic healing of flexor tendons based upon synovial fluid nutrition. *J Hand Surg* 3 : 21-30, 1978
12. McGrouther DA, Ahmed MR : Flexor tendon excursions in no man's land. *Hand* 13 : 129-141, 1981
13. Strauch B, De Moura W : Digital flexor tendon sheath, Anatomic Study. *J Hand Surg* 10A : 785-789, 1985
14. Warwick R, Williams PL : *Gray's Anatomy*. Thirty-fifth edition. Norwick, Longman Group Ltd. 1973, pp. 545-546
15. Watson HK, Light TR, Johnson TR : Checkrein resection for flexion contracture of the middle joint. *J Hand Surg* 4 : 67-71, 1979

Correspondence to :

Dr.M.Mümtaz GÜLER
GATA
Plastik ve Rekonstrüktif
Cerrahi Anabilim Dalı
Etlik
06018 ANKARA - TURKEY
Phone : 4- 325 12 11 / 1929

REFERENCES

1. Bowers WH, Wolf JW Jr, Bittinger S : The proximal interphalangeal joint volar plate I. An anatomical and biochemical study. *J. Hand Surg* 5 : 79-88, 1980
2. Brockis JG : The blood supply of the flexor and extensor tendons of the fingers in man. *J Bone and Joint Surg* 35B : 131-138, 1953
3. Cleland J : The cutaneous ligaments of the phalanges. *J of Anat and Physiol* 12 : 526-527, 1978
4. Doyle JR, Blythe WF : Anatomy of the flexor tendon sheath and pulleys of the thumb. *J Hand Surg* 2 : 149-157, 1977
5. Eaton RG : *Joint injuries of the hand*. Springfield, III Charles C Thomas Publisher. 1971, pp. 9-34
6. Gad P : The anatomy of the volar part of the capsules of the finger joints. *J Bone and Joint Surg* 49B : 362-367, 1967
7. Grayson J : The cutaneous ligaments of the digits. *J of Anat* 75 : 164-165, 1940