



Dacrocytes: A Distinct Presentation in Breast Carcinoma

Dakrositler: Meme Karsinomunda Farklı Bir Sunum

© Hamza Sümter

Uşak University Faculty of Medicine Training and Research Hospital, Department of Hematology, Uşak, Türkiye

ABSTRACT

Peripheral smear, in which blood cells are evaluated morphologically, is used as a routine in the daily hematology outpatient clinic. This procedure can sometimes play an important role and even save the patient time in the diagnosis. The patient who came to the hematology outpatient clinic with fatigue and underwent bone marrow biopsy because of dacrocyte in his peripheral smear was diagnosed with breast cancer with bone marrow metastasis. The patient was transferred to the oncology outpatient clinic for follow-up. This study was presented to emphasize the importance of peripheral smear.

Keywords: Peripheral smear, dacrocyte, breast cancer

ÖZ

Kan hücrelerinin morfolojik olarak değerlendirildiği periferik yayma, günlük hematoloji polikliniğinde rutin olarak kullanılmaktadır. Bu prosedür bazen önemli bir rol oynayabilir ve hatta tanıda hastaya zaman kazandırabilir. Yorgunluk şikayetiyle hematoloji polikliniğine gelen ve periferik yaymasındaki dakrosit nedeniyle kemik iliği biyopsisi yapılan hastaya, kemik iliği metastazlı meme kanseri tanısı konuldu. Hasta takip amacıyla onkoloji polikliniğine devredildi. Bu çalışma periferik yaymanın önemini vurgulamak amacıyla sunulmuştur.

Anahtar Sözcükler: Periferik yayma, dakrosit, meme kanseri

INTRODUCTION

Clinical history, physical examination and laboratory tests are evaluated together in the diagnosis of the disease. Although peripheral smear is used in case of numeric abnormal values in complete blood count in general medical approach, it is a basic and informative tool as much as possible in hematology practice (1). In the smear prepared with the appropriate technique, each type of blood cell (erythrocyte, leukocyte, thrombocyte) is interpreted separately. This step in diagnosis sometimes becomes an important parameter (2).

CASE REPORT

A 50-year-old woman referred to hematology in April 2022 was evaluated with malaise. Complete blood count showed wbc: 7000, anc: 2400, hb: 9,3, plt: 104,000, transaminases: normal, renal function tests: normal, folate: 10, vit B-12: 670, ferritin: 670 (normal range: 7-276). Chronic disease anaemia was considered in the primary plan due to low Hb accompanying high ferritin levels. Peripheral smear was evaluated primarily for the current picture. Hyperchromia, 2-3 dacrocytes per field, rare myeloid precursor cells and rare nucleated

erythrocytes were observed in the peripheral smear (Figure 1a-e). Erythropoietin (EPO) level was analysed as 77 (normal range: 4.3-29). Low hemoglobin level accompanying elevated EPO and appearance in peripheral smear suggested possible bone marrow pathology. The patient was also evaluated for blood loss from the gastrointestinal and urogenital systems. No occult blood was detected in the faeces. There was no complaint of hypermenorrhoea. No pathology was detected in detailed hepatitis and TORCH panel.

During follow-up, bone marrow biopsy was recommended and performed. Bone marrow pathology revealed malignant epithelial tumor metastasis with a ki-67 proliferation index between 20-30%. The tumor markers ordered secondary to this result were CA15-3: 400 U/mL (normal range: <25 U/mL), CA125: 18.3 U/mL (normal), CA19-9: 2 U/mL (normal). The patient was diagnosed with breast carcinoma on further analyses performed due to elevated CA15-3. The patient is currently being followed up in the oncology department.

DISCUSSION

In current hematology practice, common causes are primarily evaluated with anemia parameters in patients presenting with

Address for Correspondence/Yazışma Adresi: Hamza Sümter MD, Uşak University Faculty of Medicine Training and Research Hospital, Department of Hematology, Uşak, Türkiye

E-mail / E posta: hamzasumter@gmail.com

ORCID ID: orcid.org/0000-0002-0224-9438



©Copyright 2024 by Gazi University Faculty of Medicine / Gazi Medical Journal is published by Galenos Publishing House. Licensed under a Creative Commons Attribution-NonCommercial-NoDerivatives 4.0 (CC BY-NC-ND) International License

*Telif Hakkı 2024 Yazar. Gazi Üniversitesi Tıp Fakültesi adına Galenos Yayınevi tarafından yayımlanmaktadır. Creative Commons Atıf-GayriTicari-Türetilemez 4.0 (CC BY-NC-ND) Uluslararası Lisansı ile lisanslanmaktadır.

Received/Geliş Tarihi: 19.03.2023

Accepted/Kabul Tarihi: 14.05.2023

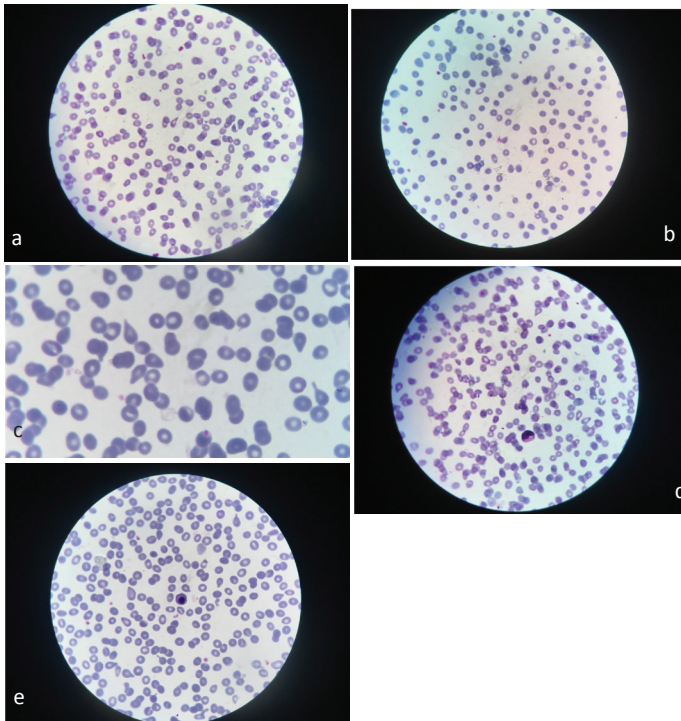


Figure 1. (a-e). Hyperchromia, 2-3 dacryocytes per field, rare myeloid precursor cells and rare nucleated erythrocytes were observed in the peripheral smear

cytopenia. In this evaluation, besides the laboratory tests, peripheral smear cannot be ignored. In microscopic examination, each cell line (erythrocyte, leukocyte, thrombocyte) is interpreted separately.

For example, erythrocytes may have size differences, hypo/hyper chromia, deformities (nucleated erythroid cell, target cell, poikilocytosis, pencil cell, sickle cell, stomatocyte, dacryocyte, etc.). Immature cells called left shift in leukocyte, hypo/hyper granulation, hypo/hyper segmentation, blasts, reactive lymphocytes constitute important clues in the diagnosis. When viewed from the aspect of thrombocyte, another cell, it is evaluated both numerically and in size.

Although peripheral smear does not make a direct diagnosis, it is as helpful as possible in the diagnosis. Unexplained cytopenia (anaemia, leukopenia, thrombocytopenia), unexplained leukocytosis,

lymphocytosis, monocytosis, acute and chronic myeloproliferative diseases (e.g. chronic myeloid leukemia), chronic lymphoproliferative diseases (e.g. chronic lymphocytic leukemia), renal and hepatic insufficiency, hyperviscosity states, paraproteinemias (e.g. Peripheral smear can be a guide in many subjects such as multiple myeloma, Waldenström macroglobulinemia), bacterial sepsis, parasitic infections, possible diseases for the presence of large platelets (Bernard Solier syndrome, May Heggelin anomaly, Wiskott Aldrich syndrome) (3-6).

CONCLUSION

In this era of molecular analyses, the peripheral smear is still effective. In this article, we aimed to draw attention to peripheral smear which is indispensable in daily hematology practice.

Ethics

Informed Consent: It was obtained.

Peer-Review: Externally peer-reviewed.

Financial Disclosure: The author declared that this study received no financial support.

REFERENCES

1. Adewoyin AS, Nwogoh B. Peripheral blood film - a review. *Ann Ib Postgrad Med* 2014; 12: 71-9.
2. Hegde RB, Prasad K, Hebbar H, Sandhya I. Peripheral blood smear analysis using image processing approach for diagnostic purposes: A review. *Biocybernetics and Biomedical Engineering* 2018; 38: 467-80.
3. Bain BJ. Diagnosis from the blood smear. *N Engl J Med* 2005; 353: 498-507.
4. K T N, Prasad K, Singh BMK. Analysis of red blood cells from peripheral blood smear images for anemia detection: a methodological review. *Med Biol Eng Comput* 2022; 60: 2445-62.
5. Mutlu H, Akca Z, Teke HU, Ugur. Evaluation of Peripheral Blood Smear for Myelodysplasia in Breast Cancer Patients who Received Adjuvant Anthracycline. *Eurasian J Med* 2011; 43: 173-6.
6. Gajendra S, Sharma R. Cytomorphological evaluation of non-haematopoietic malignancies metastasizing to the bone marrow. *Am J Blood Res* 2023; 13: 1-11.